

# Post-orthodontic retention effectiveness of two types of fixed retainers in patients aged between 12 and 35: a systematic literature review

Gómez M<sup>1</sup>, Herrera Luz E<sup>2</sup>, Suárez A<sup>3</sup>, Sánchez G<sup>4</sup>

## Abstract:

**Objective:** To identify the effectiveness of two types of fixed post-orthodontic retainers in patients aged between 12 and 35 through a systematic literature review.

**Method:** A systematic literature search was performed using the followings electronic databases: Cochrane, Pubmed, Science Direct, Isi Web Science, Scielo. Keywords: *Tooth crowding, Posttreatment, Retainer, Malocclusion, Recurrence, Orthodontic stability, Relapse.* The articles were analyzed by title, abstract and full text. The ones that fulfilled the eligibility criteria were chosen. The methodological quality of the articles selected was evaluated using the MINCIR checklist. The articles were classified using the SIGN list, where the articles were evaluated according to study design. **Results:** In the initial electronic search, 6,632 articles were identified, 15 of which fulfilled the inclusion criteria. After being analyzed, only four articles were considered to include all the quality and inclusion criteria. **Conclusions:** There is not enough scientific evidence in the publications analyzed to determine which of the two types of evaluated retainers is the most effective in post-orthodontic retention.

Keywords: Tooth crowding, posttreatment, retainer, malocclusion, recurrence, orthodontic stability, relapse.

<sup>1</sup> Orthodontist, Universidad Javeriana, Graduate

<sup>2</sup> Orthodontist, New York University, Professor, Universidad Javeriana

<sup>3</sup> Epidemiology Specialist, Universidad El Bosque, Professor, Universidad Javeriana

<sup>4</sup> Orthodontist, Universidad Javeriana, Professor, Universidad Javeriana

Received on: 20 Aug 16 - Accepted on: 24 Feb 17

## INTRODUCTION

Long-term stability after orthodontic treatment poses a serious challenge<sup>1,2</sup>. Relapse can be defined as the teeth's general tendency to return to their original position after orthodontic movement. Thilander<sup>2</sup> defines relapse as a return to the pretreatment condition. Its presence is particularly important for the clinician, as although it has been argued that the proper diagnosis and treatment planning, followed by the careful stabilization of the final results, minimize the importance of retention<sup>3</sup>, relapse occurs in a large number of cases treated<sup>3</sup> and the long-term stability of dental alignment is highly variable and unpredictable<sup>4</sup>.

In 1960, Reidel summarized conclusions regarding relapse:

1. Teeth which have been moved through bone often have a tendency to return to their former positions.
2. Arch form, particularly in the mandibular arch, cannot be permanently altered through orthodontics appliance therapy.
3. Bone and adjacent tissues must be allowed some time to reorganize around the newly positioned teeth<sup>5</sup>.

After 10 years of retention, 67% of orthodontic treatment outcomes are maintained; around half the total relapse occurs in the first two years after retention, and fixed retainers have a positive effect on PAR index<sup>3</sup>.

Between 40% and 90% of the patients treated present unacceptable dental alignment 10 to 20 years after retention, with large individual variations<sup>2</sup>. Fudalej et al.<sup>1</sup> concluded that less than 30% of patients have satisfactory alignment 20 years after retention is removed<sup>6</sup>. Relapse is greater in the lower arch (37%) compared to the upper arch (33%)<sup>7</sup>. Relapse types in orthodontics include dental crowding or spacing, increase of pre-existing vertical and horizontal overbite, and instability of Angle Class II and Class III corrections<sup>2,3,6,8</sup>.

There is wide variation in the outcome of orthodontic treatment in different people. This depends on severity and type of malocclusion, treatment approach to solve malocclusion, patients' cooperation, growth and degree of adaptation of soft and hard tissues, as well as type of retention and length of use<sup>3</sup>.

Relapse in the lower anterior sector may occur even after implementing prolonged retention in combination with mild interproximal wear, or stripping, of these teeth<sup>9</sup>. The literature focuses on researching mandibular anterior crowding relapse, probably because the stability of the alignment of these teeth is lower than that of the upper front teeth<sup>4</sup>. It has been shown that lower anterior crowding has a higher relapse rate after orthodontic treatment compared to other features of malocclusion<sup>10,11</sup>. Sampson<sup>12</sup> reported that growth rotation in the mandible is at least twice as high as in the upper jaw, which may explain, in part, the higher incidence of mandibular crowding. Postretention relapse of mandibular incisors is the first sign of the progressive instability of the orthodontic treatment. Regardless of the causes behind the

relapse, the irregularity of lower incisors seems to be the first element of mandibular crowding and the deterioration of the outcome of the treatment<sup>12</sup>, and has been considered by patients and orthodontists as treatment failure<sup>10</sup>.

Little's Irregularity Index (LII) is a widely used method to evaluate the irregularity of incisors, crowding and dental alignment after orthodontic treatment. This index measures the horizontal linear displacement of anatomic contact points of each mandibular incisor in a buccolingual direction parallel to the occlusal plane, disregarding vertical displacement, from the mesial surface of a canine to that of the other canine<sup>9</sup>. The sum of the five measurements is the LII. The higher the index, the greater the teeth's buccolingual displacement. Most studies that include the LII have used calipers to record study scores. This index categorizes the relapse of anterior teeth as: none (0-1 mm), minimal (1-3 mm), moderate (3-6 mm), or severe (greater than 6 mm)<sup>9</sup>.

Retention is one of the most widely used alternatives to control relapse. In 1973, Moyers defined retention as "the holding of teeth following orthodontic treatment in the treated position for the period of time necessary for the maintenance of the result". In 1969, Riedel defined it as "the holding of teeth in ideal aesthetic and functional positions"<sup>5,13,14</sup>.

Various devices have been used as retention. In the last few decades, fixed retainers were introduced. They have a segment of orthodontic wire attached to the teeth with previous acid etching and bonded with resin<sup>5</sup>. This retainer design, bonded to the lower anterior teeth, is aesthetic<sup>11</sup> and may be made in 0.030" or 0.032" smooth wire or 0.0215" - 0.0195" multi-strand wire, bonded with resin to the six anterior teeth or to the six anterior teeth as well as the second premolars, the latter when the first premolars have been extracted; or only to two teeth: right and left canine in the same arch (3-3)<sup>15</sup>. However, they can be made using multiple types of materials and designs. The increase in the rate of post-orthodontic irregularity could be attributed to the number of retention failures caused by implementing the wrong bonding technique, the type of material used for this purpose, and/or because of the direct wear or trauma of the retainer<sup>5,15,16</sup>.

Some authors mention that the only disadvantage of third-generation 3-3 retainers is that although the retainer bar is well outlined during manufacture, and the incisors fit snugly against the wire, there can still be slight lip movements. However, it is considered that lip movements are usually avoided by maxillary incisors when there is a normal horizontal overjet<sup>17</sup>.

As noted, there is a wide range of types of fixed retainers for retention of the lower anterior segment after orthodontic treatment. There seems to be a methodological weakness in the studies on the subject (small groups of patients or short observation periods) that restricts the evidence on the stability of orthodontic alignment with the use of fixed retainers<sup>11</sup>. It is

essential to review the available evidence-based information on this subject in order to guide orthodontists when developing post-orthodontic management protocols and to provide a clearer idea of the effectiveness of these retainers.

We conducted this review to address the controversy in the literature regarding the use of different types of fixed retainers for lower anterior teeth, especially as there is no agreement on which technique is most effective. Its aim was: *To identify the effectiveness of two types of fixed post-orthodontic retainers in patients aged between 12 and 35 through a systematic literature review.*

## **METHODS**

Type of study: Systematic literature review

We conducted a computer search of scientific publications between 1 December, 1980 and 30 April, 2013 in PubMed, Cochrane, Science Direct, ISI Web of Science using the following descriptors and boolean operators: *Orthodontic stability AND Orthodontic retainer AND malocclusion, Post orthodontic treatment AND retainer, Tooth crowding AND Orthodontic retainer, Orthodontic Relapse AND fixed orthodontic retainers, Tooth crowding AND Orthodontic retainer AND recurrence.*

We included analytical observational study designs and prognosis-type intervention designs. We included scientific articles in English and Spanish based on studies conducted with humans aged between 12 and 35.

The research started with the search of the scientific literature related to the topic in the databases described above, through the descriptors mentioned, followed by the reading of titles, abstracts and full texts. The articles selected were methodologically evaluated using the international MinCir Checklist (2013) for prognostic studies. We identified the level of evidence and grade of recommendation by applying the criteria suggested by the *SIGN (Scottish Intercollegiate Guidelines Network)*. We then selected the articles included in the final filter and analyzed them through a literature matrix, where we included: title, design of the study, variables analyzed, methods, results and main conclusions, which provided a response to each of the analysis units raised in the study.

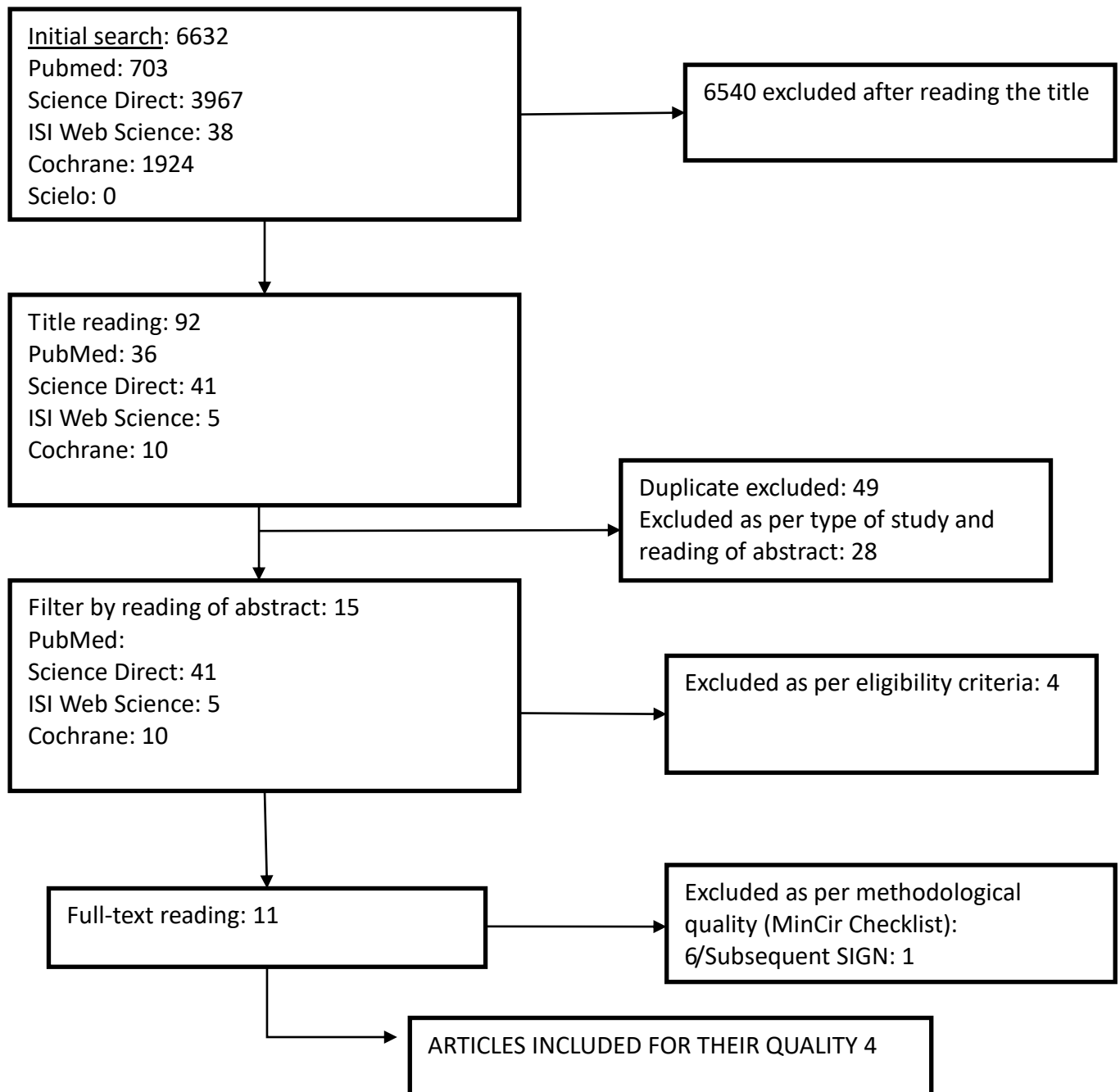
The search flowchart is described in the results. Figure 1.

## **RESULTS**

Following the search strategy described above, 6632 scientific publications were identified in the period from 1 December 1980 until 30 April 2013. After applying the different filters and taking into account the parameters included in the eligibility criteria, 15 articles were selected, of which 4 were excluded because of their methodological characteristics. (Figure

1. Flowchart). The excluded articles have clear limitations related to the size of the sample, and to the heterogeneity of the studied populations and the procedures developed to reach the research objectives.

Figure 1. Search flowchart.



The four articles selected were analytical observational studies: three intervention studies and one prognostic study.

The publications included in the final filter were classified according to the analysis units, attempting to find the answer to the PICO question of this study:

*Is post-orthodontic retention effective in patients aged between 12 and 35 regarding 2 types of fixed retainers (fixed retainer bonded to all 6 mandibular teeth [canine-to-canine retainer], and fixed retainer bonded only to the lingual surfaces of the lower canines [canine-and-canine retainer])?*

**Analysis units:**

***Effect of type of wire used to make two types of fixed retainers in post-orthodontic retention***

There is no definite pattern regarding type of material, its architecture and its diameter to make retainers. For example, Störmann and Ehmer<sup>18</sup> studied fixed canine-to-canine retainers made with wire with a diameter of 0.0215" and 0.0195" (straight wire), compared to prefabricated 3-3 fixed retainers, whose material type is not mentioned; Renkema A. et al.<sup>9</sup> evaluated 3-3 fixed retainers with wire measuring 0.027" x 0.0215" in rounded rectangular steel; In 2011, Renkema. et al.<sup>11</sup> studied fixed retainers bonded to all 6 mandibular teeth. They were made with FSW (0.0195" 3-strand, heat-treated twist wire, GAC International, Bohemia, NY) and Bolla et al.<sup>19</sup> evaluated fixed GFR retainers (glass fiber reinforced retainers) compared to multi-strand (MST) fixed retainers with passive wire with a diameter of 0.0175"; (Tables 1 and 2). However, Störmann and Ehmer found significant differences in post-orthodontic stability between canine-to-canine individual bonding, made with 0.0195" wire, which showed no irregularity, and another retainer made with 0.0215" wire with 20% relapse rate; and the 3-3 retainer that had an 80% relapse rate, during a follow-up period of 24 months after orthodontic treatment. The type of wire used for the latter, with a P value of 0,001<sup>18</sup>, is not mentioned.

Additionally, a 29% detachment rate was found for the 0.0195" canine-to-canine retainer, compared to a 53% detachment rate for the 0.0215" canine-to-canine retainer. The lowest detachment rate was 18% for the 3-3 retainer for the 24-month follow-up period<sup>18</sup>. The one-point failure was the most frequent. Only in three cases was the retainer completely detached, and in none of these cases was it aspirated, therefore there is no statistical significance<sup>18</sup>.

According to the results obtained by Renkema in 2008, when evaluating models of patients who had used a 3-3 fixed retainer, the mean irregularity index was 7.2 mm (SD 4.0) at Ts

(before starting orthodontic treatment), which decreased to 0.3 mm (SD 0.5) at T0 (after orthodontic treatment), and there was an 0.7 mm increase (SD 0.8) at T2 (2 years after treatment). From T2 to T5 (5 years after orthodontic treatment), the mean irregularity index increased to 0.9 mm (SD 0.9): a P-value of 0.004. The alignment of lower anterior teeth is stable in 85.5% of patients at T2 and in 79.1% of patients at T5<sup>9</sup>, thus showing that after 2 years of retention the observed relapse decreases. Within the group whose irregularity index increased from T0 to T5 (94 patients), in 49 patients (52.1%) the irregularity did not have the direction of the initial condition, but in 45 patients (47.9%) the irregularity had the same direction<sup>9</sup>.

The distribution of bond failures at T5 is as follows: 187 patients (79.6%) never had a failed retainer, whereas 48 patients (20.4%) had at least 1 failure. The annual failure rate was 12.1% from T0 to T2, and 6.4% from T0 to T5. P value = 0.075. The authors do not state if the statistical significance in relapse between T2 and T5 is on all the studied sample or on the patients who had some degree of retainer detachment. Therefore, it is not possible to conclude if the reason the patients relapsed is retainer detachment<sup>9</sup>.

In 2011, when studying models of patients who used fixed retainers bonded to all 6 mandibular teeth, Renkema, reported that the mean irregularity index was 5.35 mm (SD 3.47) at T5; it decreased to 0.07 mm (SD 0.23) at T0, and increased to 0.13 mm (SD 0.34) at T2. Between T2 and T5, the mean irregularity index increased to 0.15 mm (SD 0.36). (P= 0.023 for T0-T5, P= 0.162 for T0-T2, and P= 0.452 for T2-T5)<sup>11</sup>. This supports the results observed in their 2008<sup>9</sup> study regarding the decrease in relapse two years after orthodontic treatment. At T5, 151 patients (68.3%) had never had a bond failure, whereas 70 patients (31.7%) had at least 1 bond failure; however, the statistical significance for this data is not mentioned. Failures were not related to age or sex. We compared the results of this study with those obtained by Renkema et al. in 2008, who found a lower percentage of bond failure in 3-3 retainers than in canine-to-canine retainers<sup>9,11</sup>.

In 2012, Bolla et al. used reinforced glass fiber bonded to the lingual surfaces of all the lower anterior teeth as an alternative material for fixed retention. As this material has a very thorough bonding protocol, it had the lowest detachment rate among all the selected studies (11.76%) after 6 years. It was compared with the fixed retainer bonded to all the lingual surfaces of lower anterior teeth mentioned above, made with 0.0175" multi-strand stainless steel wire, which presented a 15.62% failure rate. There was an interproximal fracture in 8.82% of GFR retainers, and in 15.62% of multi-strand wire retainers, probably due to their reduced diameter. However, the differences between these two types of retainers were not statistically significant<sup>19</sup>.

**Table 1. Summary of the report on the effectiveness of lower fixed retainers**

Author	Retainer design	Study sample	Retention time	Relapse, irregularity
<b>Störmann, Ehmer, 2002.</b> <sup>18</sup>	<ul style="list-style-type: none"> <li>• 0.0195" (multi-strand) bonded to all lower anterior teeth</li> <li>• 0.0215" (multi-strand) bonded to all lower anterior teeth</li> <li>• Straight wire (3-3 lower).</li> </ul>	31 patients 38 patients 34 patients	2 years	None 20% 80% P: 0.001
<b>Renkema et al. 2008</b> <sup>9</sup>	<ul style="list-style-type: none"> <li>• 0.027 x 0.0215" in rounded rectangular steel (3-3 lower).</li> </ul>	235. Patient models	5 years	-0.3 mm (SD 0.5) at T0 -0.9 mm (SD 0.9) at T5 P= 0.004
<b>Renkema et al., 2011</b> <sup>11</sup>	<ul style="list-style-type: none"> <li>• FSW (0.0195" 3-strand twist wire, bonded to all 6 lower anterior teeth)</li> </ul>	221. Patient models	5 years	-0.07 mm (SD 0.23) at T0 -0.15 mm (SD 0.36) at T5 P= 0.023 from t0 to t5
<b>Renkema et al., 2012</b> <sup>19</sup>	<ul style="list-style-type: none"> <li>• GFR (glass fiber reinforced retainers, bonded to all 6 lower anterior teeth)</li> <li>• MST (0.0175" multi-strand wire bonded to all 6 lower anterior teeth)</li> </ul>	40 patients 45 patients	6 years	None reported

**Table 2. Summary of the report on the bond failure rate of lower fixed retainers**

Author	Retainer design	Study sample	Retention time	Retainer failures
<b>Störmann, Ehmer, 2002</b> <sup>18</sup>	<ul style="list-style-type: none"> <li>• 0.0195" (multi-strand) bonded to all lower anterior teeth</li> <li>• 0.0215" (multi-strand) bonded to all lower anterior teeth</li> <li>• Straight wire (3-3 lower).</li> </ul>	31 patients 38 patients 34 patients	2 years	29% 53% 18% No P value
<b>Renkema et al. 2008</b> <sup>9</sup>	<ul style="list-style-type: none"> <li>• 0.027 x 0.0215" in rounded rectangular steel (3-3 lower).</li> </ul>	235. Patient models	5 years	20.4% of patients had failures at T5. P: 0.075
<b>Renkema et al., 2011</b> <sup>11</sup>	<ul style="list-style-type: none"> <li>• FSW (0.0195" 3-strand twist wire, bonded to</li> </ul>	221. Patient models	5 years	31.7% of patients had failures at T5. No P value reported



	all 6 lower anterior teeth)			
<b>Renkema et al., 2012<sup>19</sup></b>	<ul style="list-style-type: none"> <li>GFR (glass fiber reinforced retainers, bonded to all 6 lower anterior teeth)</li> <li>MST (0.0175" multi-strand wire bonded to all 6 lower anterior teeth)</li> </ul>	40 patients  45 patients	6 years	-11.76%  -15.62%  No P value

Analyzing the second analysis unit, the ***Influence of the retainer bonding technique on posttreatment stability***, we found that most papers do not explain clearly the bonding technique used, and some of them do not even mention it. However, in 2002, Störmann and Ehmer<sup>18</sup> state that when inserting the retainers they use two techniques: under dry field conditions (37% detachment rate) and under relatively dry conditions (32% detachment rate). They found no statistically significant difference between the two techniques<sup>18</sup>. When studying the use of two types of resin for retainer bonding, they found that self-cure resin had a 27% detachment rate, and light-curing resin a 73% detachment rate. However, though they mention that this data is statistically significant, they do not show the statistical significance with a P value.

Bolla et al. were the only ones to explain the bonding technique in detail. They used a rubber dam to create a dry field, and an additional agent called Oxiguard, insulating barrier (Oxiguard II, Panavia 21, Kuraray Medical Inc., Okayama, Japan) after placing and light-curing the resin. Finally, they light-cured each tooth for an additional 20 seconds and then inserted the retainer on the lingual surfaces of mandibular anterior teeth, in the most incisal direction possible, avoiding contact with the taste buds<sup>19</sup>.

***Relationship between the degree of severity of the initial malocclusion in the effectiveness of fixed retainers bonded to all 6 mandibular teeth compared with fixed retainers bonded only to the mandibular canines.***

Papers are not specific when it comes to describing patients' initial malocclusion, and they include patients with all types of malocclusion and different ages. Some are treated with extractions and others without extractions. Authors do not take into account the degree of crowding to classify patients into different groups, nor do they connect the initial malocclusion to the results obtained. Störmann and Ehmer studied 103 patients aged between 13 and 17,

previously treated with fixed and removable appliances<sup>18</sup>; In 2008, Renkema et al. classified patient models according to Angle's classification, which was obtained from the right side of the models; the mean age at the beginning of orthodontic treatment was 12.8 years (SD 2.7) and 15.6 years (SD 2.7) at the end of orthodontic treatment. They stated if the patients had been treated with extractions: divided into four categories, no premolars were extracted in any of the 4 quadrants; there were no extractions in the mandibular arch, and 1 premolar or first maxillary molar was removed in both quadrants; there were no extractions in the mandibular arch and the second molar in both quadrants was removed, with a mean irregularity index of 7.2 mm (SD 4.0) at Ts<sup>9</sup>; Renkema et al. 2011, studied 25 class I patient models, 191 class II models and 5 class III models. The mean age was 13.4 years (SD 4.2) at the start of the orthodontic treatment, and 16.3 years (SD 4.2) at the end of the treatment. The mean treatment duration was 2.9 years (SD 0.9). Distribution of extraction categories: 151 patients without extractions (68.3%), 35 with 1 premolar extraction in all quadrants (15.9%), 21 (9.5%) without extractions, and removal of 1 premolar or first molar in both maxillary quadrants, and 14 (6.3%) in the rest of the group and with a mean irregularity index at TS of 5.35 mm (SD 3.47)<sup>11</sup>. In 2012, Bolla et al. studied 85 adults, 29 men, mean age 23.7 years; 56 women, mean age 21.9 years. All the patients were treated with fixed orthodontic appliances and selected with the following criteria: good hygiene and periodontal health. The degree of crowding before treatment is classified as moderate (2.2 mm maxillary in the mandible in the anterior segment). Class I at the end of the treatment, overbite between 1 and 3 mm, a Bolton anterior analysis is correct. No extractions. Divided into two groups: 40 patients (12 men, mean age: 23.4 years; 28 women, mean age 20.2 years). They were treated with GFR (glass fiber reinforced retainers); 45 patients (17 men, mean age 24.1 years, 28 women, mean age 22.6 years, were treated with fixed 0.0175" multi-strand passive wire retainers (MST)<sup>19</sup>. According to these descriptions, Bolla's patients had a malocclusion with moderate crowding before treatment<sup>19</sup>, whereas some of Renkema's<sup>9,11</sup> patients presented severe pre-treatment crowding.

In the last analysis unit, which seeks to analyze the ***influence of time of use of two types of fixed retainer in the lower anterior segment on the effectiveness of the posttreatment retention***, we found the studies do not have the same follow-up time. In general we observed that two years after treatment the relapse continues, but at much lower rate than that observed in the first two years. The bond failure rate decreases over time in the selected studies.

## DISCUSSION

Regarding the effect of the type of wire used to make two types of posttreatment fixed retainers, Störmann and Ehmer<sup>18</sup> found significant differences in post-orthodontic stability. They suggest that mandibular retainers bonded to all teeth, from canine to canine, are more effective in preserving alignment than 3-3 retainers. The 0.0195" mandibular canine-to-canine retainer did not show any degree of irregularity. The 0.0215" retainer had a 20% relapse rate, and the 3-3 retainer had an 80% relapse rate, although they do not mention the type of wire used for the latter<sup>18</sup>. In 1996, Artun et al.<sup>20</sup> found that the 0.0205" spiral wire retainer bonded to all 6 mandibular teeth had a 0.30 mm irregularity index after treatment, which stayed the same three years after treatment (there were no changes in the irregularity index). This differs from what happened with the 0.032" straight wire retainer bonded only to the canines, which had an initial irregularity index of 0.65 mm, which was 1.19 mm three years after treatment (almost double). The 0.032" 3-3 spiral wire lower retainer had an incisor irregularity of 0.20 mm after treatment, and three years later it was 0.36 mm (small increase). They conclude that despite the use of a suitable insertion technique, retainer failures occur in approximately 20% of the different bonding designs for lower canine-to-canine fixed retainers.

Furthermore, when comparing the 2008 and 2011 Renkema's papers, we observed that the **irregularity rate** obtained in the canine-to-canine study<sup>11</sup> is, to a large extent, lower than that obtained for the 3-3 retainer; This means that the FSW retainer (bonded to all lower anterior teeth from canine to canine) provides better results when preserving alignment than the 3-3 0.0215" x 0,027" wire retainer made with rounded rectangular steel. These results relate to those obtained by Al-Nimri et al.<sup>21</sup>, who compared fixed mandibular retainers bonded to all 6 mandibular teeth from canine to canine made with 0.015" multi-strand wire (0.38 mm posttreatment irregularity and 1.92 mm after a year) with 3-3 lower anterior fixed retainers made with 0.036 round wire (0.32 mm posttreatment irregularity and 3.08 mm after a year) over a period of 12 months, (P= 0,002). They concluded that the retainer bonded to all the lower anterior teeth is more effective at preserving the alignment of the lower incisors. The use of 3-3 retainers leaves incisors free to move outside the arch<sup>21</sup>. Zachrisson, reported by Störmann and Ehmer, supports this assessment, and to prevent relapse, he overcorrects relapse-prone areas and then allows the teeth to slide into their ideal position<sup>18,22</sup>.

We found that in Renkema et al. 2011, 76.2% of patients had the irregularity in the direction of the initial irregularity, which is inconsistent with the results obtained by Renkema et al. in 2008, who found that at least half the rotations and displacements occurred in the opposite direction to the initial one; however, this event is not explained<sup>9,11</sup>.

**Regarding the influence of the bonding technique on posttreatment stability**, in 2002, Störmann and Ehmer found that as the number of failures is similar in relatively dry

conditions (32% detachment rate) compared with dry field conditions (37% detachment rate), the authors recommend the use of relatively dry field conditions for retainer bonding, as they involve less time and effort.

Failures in the wire/resin interface are usually associated to loss of resin due to abrasion<sup>23</sup>. In 2002, Störmann and Ehmer<sup>18</sup> found that when using self-cure resin (Concise), there was a 27% detachment rate, and light-cure resin (Heliosit) had a 73% detachment rate. They state that this may be because Heliosit has a lower proportion of filling particles, resulting in reduced resistance to forces of pressure, tension, deformation and abrasion. These results are supported by Bearn et al., who in 1995 found that a greater force is required to detach the wire from Concise Orthodontic (3M Unitek) than Heliosit resin (Vivadent). The in vitro abrasion resistance testing found that Heliosit has poor abrasion resistance, whereas Concise has abrasion resistance comparable to restorative resins ( $p < 0.05$ )<sup>23</sup>. These findings support the fact that self-cure composite such as Concise or similar products should be used to bond lower anterior fixed retainers<sup>18</sup>.

Mechanical forces, lever action at the retainer resulting from habits or mastication forces, lead to bond failure<sup>18</sup>. The failures can be inherent, resulting from an inadequate bonding technique, or acquired, from wear or direct trauma to the retainer. The differences in failure rates can also be attributed to various bonding techniques and materials<sup>9</sup>. Another factor that may lead to bond failure is the lack of precision when making and adapting the appliance, that is to say, lack of close contact with the incisors and lack of absolute wire passivity<sup>18</sup>. In 2006, Littlewood et al.<sup>24</sup> analyzed the stability of the lower-incisor alignment with the use of a fixed retainer bonded to all 6 mandibular teeth for 3 years, and found that in patients whose retainer had not failed, there was no increase in incisor irregularity<sup>24</sup>.

The period between retainer bond failure and the time when the patient reports the event is essential for the relapse to take place. This is why, when the retainer is inserted, patients should be instructed on the necessary care, and also that if they feel the retainer has detached, they should report it as soon as possible. It is very important that patients and general dentists report posttreatment changes immediately, to prevent the need for retreatment<sup>11</sup>. Patients with fixed retainers bonded to all the lingual surfaces from canine to canine may not be aware that there is a bond failure, which is a limitation. Conversely, with a 3-3 fixed retainer, when one end becomes detached, the patient notices immediately.

In 2002, Störmann and Ehmer<sup>18</sup> found that thicker retainer wire (wire with a diameter of 0.0215", bonded to all the lingual surfaces of the lower inferior teeth) had a higher detachment rate due to increased rigidity (53% in a 24-month follow-up period). Zachrisson, cited by Störmann and Ehmer in 2002<sup>18</sup>, recommends using wire diameters that allow for physiologic tooth movement, especially when there is periodontal risk. Given its rigidity, a

0.0215" wire will exhibit higher shearing forces at the bonding sites, thus favoring bond failure. The results obtained by Störmann and Ehmer<sup>18</sup> regarding bond failure rates (29% for the retainer bonded to all surfaces of the lower anterior teeth with 0.0195" wire) and stability (they observed no degree of irregularity) of the lower anterior segment, suggest that 0.0195" multi-strand wire is more effective for long-term retention.

Zachrisson, cited by Störmann and Ehmer<sup>18</sup>, prefers the use of lower 3-3 0.032" retainers, and reports an 8.4% detachment rate over a period of 1.9–3.7 years; this failure rate is much lower than the rate mentioned by the authors for lower 3-3 retainers (18% 3 for a 2-year follow-up period). Despite these changes in the irregularity index, there was an 80% relapse rate for this type of retainer<sup>18</sup>.

When comparing the results of the *2008 and 2011 studies by Renkema*, we found that the failure rate was higher in the study of retainers bonded to all the lingual surfaces of the lower anterior teeth. The patients in the 2008 study received the retainer between 1985 and 1993, and those of the 2011 study between 1995 and 2000. We must remember that bonding materials have evolved in recent years. Durability has also increased, therefore resistance to bond failure has improved, which has led to decreasing failure rates<sup>9</sup>. These results are related to those obtained in 2009 by Al-Nimri et al.<sup>21</sup>, who found that the 0.015" multi-strand retainer bonded to all mandibular teeth failed more frequently than the 3-3 0.036" round wire retainer (30% and 13% respectively), but this was not statistically significant (P:0.325<sup>21</sup>). In general, these results contradict those obtained by Artun et al.<sup>20</sup> in 1996, who studied 3 types of lower anterior fixed retainers: 3-3 lower fixed retainers made in 0.032" thick plain wire had a 30.8% detachment rate; 3-3 lower fixed retainers made of 0.032" thick spiral wire had a 9.1% detachment rate; and the 0.0205" retainer made in flexible spiral wire bonded to all lower anterior surfaces had a 27.3% detachment rate in a 3-year study period<sup>20</sup>.

In 2009, Lee and Mills found that the V-loop 0.016" fixed retainer made in stainless steel black Australian wire had a slightly higher failure rate (14.3%) than the 0.0175" straight stainless steel multi-strand wire retainer (12.4%) for a 6-month follow-up period, but the difference was not statistically significant. This study includes failure rates for fixed upper and lower retainers. However, we must remember that straight retainers, such as the SW retainer, do not allow the normal use of floss, and require the use of a threader, as well as the patient's additional effort and time. The V-loop design allows the floss easy access and is flexible enough to allow for physiological tooth movements, but the variation of this design shows no difference in the success or failure of the retention<sup>25</sup>. These results are consistent with those found by Bolla et al. in 2012, who found differences in failure rate according to the architecture and material of the fixed retainer, but they were not statistically significant. This

study included glass fiber reinforced retainers bonded to all lower surfaces from canine to canine, which had a 11.46% bond failure, compared to the 0.0175" multi-strand stainless steel retainers bonded to all the lingual surfaces from canine to canine, which had a 22.22% failure rate in a 6-year follow-up<sup>19</sup>. The fiberglass GFR retainer had an 8.82% rate of interproximal fracture<sup>19</sup>, unlike Ardeshna, who found that the average duration of GFR retainers used in 51 patients was 7.6 months, and only 33% lasted 1 year. Furthermore, of the 76 retainers part of the follow-up, 54 (71%) presented bond failure, bonding being the main cause of the failure; only 5% failed due to glass fiber breakage<sup>26</sup>.

***Regarding the relationship between the degree of severity of the initial malocclusion in the effectiveness of fixed retainers bonded to all 6 mandibular teeth compared with fixed retainers bonded only to the mandibular canines.***

The conclusions in the selected articles agree that the only factor leading to posttreatment relapse in the lower anterior segment with the use of fixed retainers is ***retainer bond failure***, and not so much pretreatment irregularity, age when starting treatment, sex, length of treatment, if the patient had teeth removed or not, if there are sagittal contacts between incisors after treatment, changes in the distance between canines, or irregularity at T0<sup>9,11,18</sup>.

The failure rate of the retainer has been an important factor to consider in each of the studies analyzed, as this failure rate seems to favor relapse in orthodontics. However, in 2011, Renkema et al. noted that only 30% of patients with retainer bond failure had increased irregularity<sup>11</sup>. Freitas et al.<sup>10</sup> found no connection between pre-treatment factors and posttreatment relapse, and analyzed patients with moderate vertical and horizontal growth patterns. In 1993, Freitas found a connection between the growth pattern and crowding relapse. The vertical growth pattern showed greater crowding relapse than the horizontal growth pattern. Perhaps these results were obtained because Freitas included patients with extreme vertical and horizontal growth patterns in his study. Similar results were observed regarding the connection between initial crowding and relapse, but again, Freitas et al.<sup>10</sup> compare their results, in which there was no relationship between the initial degree of crowding and relapse, when compared with Kahl-Nieke et al.<sup>28</sup> and Årtun et al.<sup>29</sup>, who did find a connection between initial crowding and posttreatment relapse, but these authors studied patients whose initial crowding was severe<sup>27</sup>. We could therefore presume, but not conclude, that extreme factors present in patients before treatment may influence the degree of posttreatment relapse, even with the use of fixed retainers; but when these factors are average, they do not affect the results.

***Regarding the influence of time of use of two types of fixed retainer in the lower anterior segment on the effectiveness of the posttreatment retention***, Störmann and Ehmer<sup>18</sup> report decreasing bond failure throughout the study. These authors report that this finding may be explained by the adaptation of the patient to the retainer over time, as well as

the initial bond failures<sup>18,30</sup>. Furthermore, in 2008, Renkema et al. found that the failure rates (per year) were 12.1% from T0 to T2, and 6.4% from T0 to T5<sup>9</sup>. In 2011, Renkema et al. found that the yearly failure rate was greater in the first 2 years after treatment (32% from T0 to T2, and 17.6% from T0 to T5)<sup>11</sup>. This is supported by the results obtained by Yami et al., who found that about half the relapse rate, measured with the PAR index, occurred in the first two years after retention<sup>3</sup>, thus supporting the results of Störmann and Ehmer regarding the decline of bond failures as time goes by<sup>18</sup>. The increase in tooth mobility in the initial posttreatment period might favor detachment<sup>11</sup>. In 1991, Zachrisson and Dahl reported that bond failure in canine-to-canine fixed retainers bonded to all tooth surfaces made in 3SW spiral 3-strand wire measuring 0.0215" or 0.0195" usually occurred within the first year after treatment<sup>31</sup>. This is very useful data for retention, as it leads us to implement protocols where retention controls must be carried out more thoroughly in the first two years after treatment.

## **CONCLUSIONS**

There is not enough scientific evidence in the publications analyzed to determine which of the two types of evaluated retainers is most effective in post-orthodontic retention.

We identified that relapse rates and rates of lower anterior fixed retainer failure do not follow a definite pattern, probably because of the heterogeneity of the papers regarding the selection of the patients and the type of malocclusion. Also because in some cases the type malocclusion is not considered to subdivide the patients to study, and the measurement time is not standardized. We noted that there is not a clear pattern regarding type of material, its architecture and its diameter when making retainers. Additionally, some studies do not report the statistical significance, therefore, it is not possible to conclude if the results are statistically significant or not.

It is necessary to conduct further studies involving larger groups of patients with long observation periods.

1. The 3-3 lower anterior fixed retainer shows a lower detachment rate, but a higher relapse rate than the canine-to-canine fixed retainer bonded to all the teeth. Therefore, the lower anterior fixed retainer bonded to all the mandibular teeth is considered more effective in post-orthodontic retention; also, it has a greater of detachment rate because it involves a larger number of teeth on the retainer.
2. Most publications do not clearly explain the bonding technique used, and some do not even mention it. However, we found that the bonding techniques of lower anterior fixed retainers under dry field and relatively dry field conditions are similar regarding their effectiveness when assessing the detachment rate of fixed retainers.
3. The articles do not specifically describe the patients' initial malocclusion, and include population diagnosed with different types of malocclusion. Some patients underwent extractions, whereas some authors do not mention this factor.  
Authors do not take into account the degree of crowding to classify patients into different groups, and they do not relate initial malocclusion to the results obtained.
4. There was a decreasing failure rate over time in the selected studies. It was generally observed that two years after treatment, relapse continued, but at a rate lower than that the one observed in the first two years.

## **REFERENCES**

1. Fudalej P, Rothe LE, Bollen AM. Effects of posttreatment skeletal maturity measured with the cervical vertebral maturation method on incisor alignment relapse. *Am J Orthod Dentofacial Orthop.* 2008 Aug;134(2):238-44.



2. Thilander B. Biological Basis for Orthodontic Relapse. *Semin Orthod* 2000 Sep; 6 (3):195-205.
3. Al Yami EA, Kuijpers-Jagtman AM, Van't Hof MA. Stability of orthodontic treatment outcome: Follow-up until 10 years postretention. *Am J Orthod Dentofacial Orthop.* 1999 Mar;115(3):300-4
4. Quaglio CL, De Freitas KM, De Freitas MR, Janson G, Enriquez JF. Stability and relapse of maxillary anterior crowding treatment in Class I and Class II Division 1 malocclusions. *Am J Orthod Dentofacial Orthop.* 2011 Jun;139(6):768-74
5. Bearn DR. Bonded orthodontic retainers: A review. *Am J Orthod Dentofacial Orthop.* 1995 Aug;108(2):207-13.
6. Maza P, Rodríguez M. Recidiva en ortodoncia. *Odous Científica* 2005 Jul - Dec. VI (2):70-77.
7. Cajiao A, Martínez R. Análisis de la estabilidad dental de los tratamientos de ortodoncia realizados en la Pontificia Universidad Javeriana. *Univers Odont* 1993; 12(24):39-45.
8. Thilander B. Orthodontic relapse versus natural development. *Am J Orthod Dentofacial Orthop.*2000.117(5): 562-3
9. Renkema AM, Al-Assad S, Bronkhorst E, Weinde S, Katsaros C, Lisson JA. Effectiveness of lingual retainers bonded to the canines in preventing mandibular incisor relapse. *Am J Orthod Dentofacial Orthop.* 2008 Aug;134(2):179e1-8.
10. Freitas KM, de Freitas MR, Henriquez JF, Pinzan A, Janson G. Postretention relapse of mandibular anterior crowding in patients treated without mandibular premolar extraction. *Am J Orthod Dentofacial Orthop.* 2004 Apr;125(4):480-7.
11. Renkema AM, Renkema A, Bronkhorst E, Katsaros C. Long-term effectiveness of canine-to-canine bonded flexible spiral wire lingual retainers. *Am J Orthod Dentofacial Orthop.* 2011 May;139(5):614-21.
12. Sampson WJ. Current controversies in late incisor crowding. *Ann Acad Med Singapore.* 1995 Jan;24(1):129-37
13. Ormiston JP, Huang GJ, Little RM, Decker JD, Seuk GD, Wash S. Retrospective analysis of long-term stable and unstable orthodontic treatment outcomes. *Am J Orthod Dentofacial Orthop.* 2005 Nov;128(5):568-74
14. Littlewood SJ, Millett DT, Doubleday B, Bearn DR, Worthington HV. Orthodontic retention: A systematic review. *J Orthod.* 2006 Sep;33(3):205-12.
15. Heymman GC, Grauer D, Swift EJ Jr. Contemporary Approaches to Orthodontic Retention. *J Esthet Restor Dent.* 2012 Apr;24(2):83-7.

16. Levin L, Samorodnitzky-Naveh GR, Machtei EE. The Association of Orthodontic Treatment and Fixed Retainers with Gingival Health. *J Periodontol.* 2008 Nov;79(11):2087-92
17. Zachrisson BJ. Third-Generation Mandibular Bonded Lingual 3-3 Retainer. *J Clin Orthod.* 1995 Jan;29(1):39-48.
18. Störmann I, Ehmer U. A Prospective Randomized Study of Different Retainer Types. *J Orofac Orthop.* 2002 Jan;63(1):42-50.
19. Bolla E, Cozzani M, Doldo T, Fontana M. Failure evaluation after a 6-year retention period: A comparison between glass fiber reinforced (GFR) and multistranded bonded retainers. *Int Orthod.* 2012 Mar;10(1):16-28.
20. Artun J, Spadafora AT, Shipiro PA. A 3-year follow-up study of various types of orthodontic canine-to-canine retainers. *Eur J Orthod.* 1997 Oct;19(5):501-9.
21. Al.Nimri K, Al Habashnet R, Obeidat M. Gingival health and relapse tendency: a prospective study of two types of lower fixed retainers. *Aust Orthod J.* 2009 Nov;25(2):142-6
22. Zachrisson BU. On excellence in finishing, Part 2. *Journal of Clinical Orthodontics: JCO* 1986, 20(8):536-556.
23. Beam D, Gordon P, and Aird J. Bonded orthodontic retainers: The wire-composite interface. *Am J Orthod Dentofacial Orthop.* 1997 Jan;111(1):67-74
24. Littlewood SJ, Millett DT, Doubleday B, Bearn DR, Worthington HV Retention procedures for stabilizing tooth position after treatment with orthodontic braces. *Cochrane Database Syst Rev.* 2006 Jan 25;(1):CD002283.
25. Lee KD, Mills CM. Bond failure rates for V-loop vs straight wire lingual retainers. *Am J Orthod Dentofacial Orthop.* 2009 Apr;135(4):502-6
26. Ardeshtna AP. Clinical evaluation of fiber-reinforced-plastic bonded orthodontic retainers. *Am J Orthod Dentofacial Orthop.* 2011 Jun;139(6):761-7
27. Freitas MR. Relapse of mandibular anterior crowding in patients treated orthodontically, with extractions of four first premolars, 5 and 10 years postretention. A cephalometric and model study. Bauru, Brazil: University of Sao Paulo; 1993.
28. Kahl-Nieke B, Fischbach H, Schwarze CW. Post-retention crowding and incisor irregularity: the long-term follow-up evaluation of stability and relapse. *Br J Orthod.* 1995 Aug;22(3):249-57
29. Årtun J, Garol JD, Little RM. Long-term stability of mandibular incisors following successful treatment of Class II, Division 1, malocclusions. *Angle Orthod.* 1996;66(3):229-38
30. Zachrisson BU. The bonded lingual retainer and multiple spacing of anterior teeth. *Swed Dent J Suppl.* 1982;15:247-55

31. Dahl EH, Zachrisson BU. Long-term experience with direct-bonded lingual retainers.  
J Clin Orthod. 1991 Oct;25(10):619-30

Gustavo Sánchez Vallejo: [gustavo.sanchez@javeriana.edu.co](mailto:gustavo.sanchez@javeriana.edu.co)