

Oral metastasis of renal cell carcinoma. A case report and literature review

Metástasis oral de carcinoma de células renales. A propósito de un caso y revisión de la literatura

Metástase oral de carcinoma de células renais. Relato de um caso e revisão da literatura

Florencia Santerini Baez¹,  0000-0003-3537-8305

Elizabeth Pedreira Collazo²,  0000-0002-1680-2337



DOI: 10.22592/ode2022n39e408

Abstract

Metastatic tumors to the oral cavity are rare, representing only 1% of malignant oral neoplasms. These metastatic tumors occur more frequently in the jaws than in soft oral tissues.

This article describes the case of a 75-year-old patient with a history of clear cell renal carcinoma who seeks care because of the sudden appearance of a tumor lesion in the upper left alveolar ridge. An excision biopsy was performed with a presumptive diagnosis of a metastatic tumor or potential reactive lesion. The pathology report confirmed the diagnosis of renal cell carcinoma metastasis.

Oral metastatic tumors usually present a bad prognosis with a low survival rate. It is important to examine patients thoroughly and consider their medical records, as they are sometimes diagnosed late.

Keywords: oral metastasis, renal cell carcinoma, oral mucosa.

¹Assistant Professor—4th degree. Department of Pathology, Oral & Maxillofacial Semiology and Clinical Stomatology. School of Dentistry. Universidad de la República. Uruguay. Prof. Associate Professor—3rd Degree. Dentistry Department of Hospital de Clínicas. Specialist in Oral & Maxillofacial Surgery and Traumatology. flocsante@gmail.com

²Associate Professor. 3rd Degree. Department of Pathology, Oral & Maxillofacial Semiology and Clinical Stomatology. School of Dentistry. Universidad de la República. Uruguay. Specialist in Oral & Maxillofacial Surgery and Traumatology

Received on: 22/03/2021 - Accepted on: 16/12/2021

Resumen

Los tumores metastásicos en cavidad oral son pocos frecuentes, representan el 1% de las neoplasias malignas orales, son relativamente más frecuentes en los maxilares, respecto a aquellos localizados en los tejidos blandos orales.

Se describe el caso de una paciente de 75 años de edad, con antecedentes de carcinoma renal de células claras, que consulta por la aparición repentina de una lesión tumoral en reborde alveolar superior izquierdo. Se realizó la biopsia exéresis con diagnóstico presuntivo de tumor metastásico o posible lesión reactiva. El informe anátomo - patológico confirma el diagnóstico de metástasis de un carcinoma renal.

Las metástasis orales tienen un pronóstico generalmente malo, compromete la supervivencia, por lo que es importante realizar un exhaustivo estudio del paciente y considerar sus antecedentes, ya que en ocasiones son diagnosticadas tardíamente.

Palabras clave: Metástasis oral, carcinoma de células renales, mucosa oral.

Introduction

Renal carcinoma metastasis to the head and neck region is rare. The literature shows cases of late metastasis, even decades after surgical excision of the primary tumor. The nose and paranasal sinuses are the most affected areas, followed by the oral cavity.⁽¹⁾

The jaws and soft tissues of the oral cavity are rare sites for metastatic spread; only about 1% of oral malignancies are attributed to metastases.⁽²⁾ Diagnosing these metastases is challenging due to their rarity and the importance of early detection. Differential diagnoses with benign oral inflammatory and reactive lesions and primary malignant tumors should be considered.⁽³⁻⁷⁾

Oral metastatic lesions are divided into mucosal and maxillary metastases given the differences

Resumo

Os tumores metastásicos na cavidade oral são raros, representam 1% das neoplasias malignas orais, sendo relativamente mais frequentes nos ossos maxilares enquanto aos localizados nos tecidos moles orais.

Descreve-se o caso de uma mulher de 75 anos com história de carcinoma renal de células claras, que consultou com queixa de lesão tumoral localizada na crista alveolar superior esquerda. Uma biópsia foi feita com diagnóstico clínico presuntivo de tumor metastático ou possível lesão reativa. O laudo anátomopatológico confirmou o diagnóstico de metástase de carcinoma renal.

As metástases orais geralmente têm um prognóstico ruim, com baixa sobrevivência, portanto é importante fazer um estudo exhaustivo do paciente e tomar em conta sua história, já que às vezes o diagnóstico é tardio.

Palavras-chave: Metástase oral, carcinoma de células renais, mucosa oral.

in presentation, primary site, and likely pathogenesis.⁽⁵⁾

Metastases to the jaws are twice as frequent as those to the oral soft tissues.^(6,8) The mandible is the most commonly affected area, followed by the molar area, the premolar area, and the angle-ramus region.^(4,6,8) The gingiva is the oral soft tissue most frequently affected (60%), followed by the tongue (18%).⁽⁵⁻⁸⁾ Almost any malignant tumor can metastasize to the oral cavity. The origin of metastatic lesions differs between genders. The most common primary sites in men are the lung, kidney, liver, and prostate, and in women, breasts, the uterus, ovaries, kidney, and rectum. Some tumors like prostate and breast cancer prefer the jaws as a metastatic target.⁽⁶⁾

The prognosis of a patient with oral metastasis is

generally poor, with an average survival rate of seven months.⁽⁹⁾ Treatment options in most cases include surgical resection, sometimes combined with radiotherapy and/or chemotherapy. As oral metastases result from generalized disease, treatment options are sometimes limited to palliative care to improve quality of life, feeding, and airway patency.⁽⁹⁾

Clinical case description

The patient was a 75-year-old female who was a retired piano teacher from the Department of Cerro Largo, Uruguay. She was referred to the Department of Pathology, Oral & Maxillofacial Semiology and Clinical Stomatology, School of Dentistry, UdelaR, due to a one-week evolution tumor lesion in the anterosuperior sector of the maxilla.

The medical history showed that the patient had started suffering asymptomatic gingival bleeding 12 days before with no apparent origin. She consulted a dentist, who prescribed amoxicillin 875 mg, and clavulanic acid 125 mg every 8 hours for 6 days, with no response. The patient then reported the appearance of a tumor that had significantly increased in volume in the last 6 days. It was painless, with intense bleeding, and prevented her from using her removable upper partial denture. During the examination, a bleeding and asymptomatic tumor lesion was found in the 2.2 region. Her medical history showed that she was a type II diabetic patient that controlled the disease with diet and oral hypoglycemic agents, glibenclamide 5 mg and metformin hydrochloride 10 mg. She reported achalasia diagnosed

four years before. She had a cardiac arrhythmia and had had a pacemaker for four years. She had atrophy of the left heart valve and was awaiting valve surgery. She had had a total right nephrectomy two years before as the only treatment. She did not bring a histopathology report to the consultation and stated that she did not know the nature of the renal lesion that gave rise to such treatment. The patient did not report tobacco, alcohol, or drug use.

On general examination, the woman was an outpatient, obese, had difficulty walking, had a slow gait, and was accompanied by her son. She was well oriented, lucid, and cooperative.

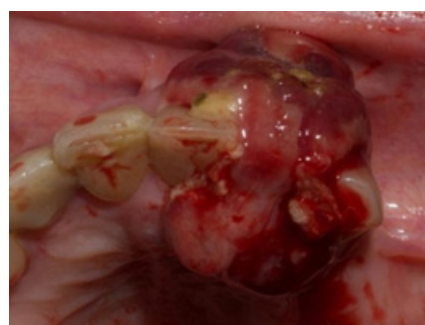
The extraoral examination showed facial asymmetry due to deformation of the left upper lip, which was displaced by the underlying tumor, preventing proper lip competence. A brownish tumor appeared in the oral cleft. No adenomegaly was detected.

The upper and lower arches were partially edentulous. A localized tumor was detected in the left maxillary alveolar ridge. It involved teeth 2.1 to 2.3. It extended in the vestibular-palatal direction, from 1 cm inside the sulcus to 1 cm of the palatal mucosa. Tooth 2.2 was clinically missing. The lesion had defined boundaries of approximately 3 cm. It partially covered the crowns of the adjacent teeth, was oval, had an irregular and lobular surface, was consistent, bright red with violet areas and other yellowish-white areas. It had a bleeding texture, sessile implantation, and was painless. Grade 2 mobility of teeth 2.1 and 2.3 was also observed (fig. 1 and 2).

Figure 1: Front intraoral view of maxillary left-side gingival tumor

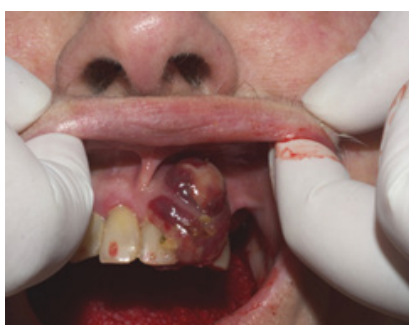

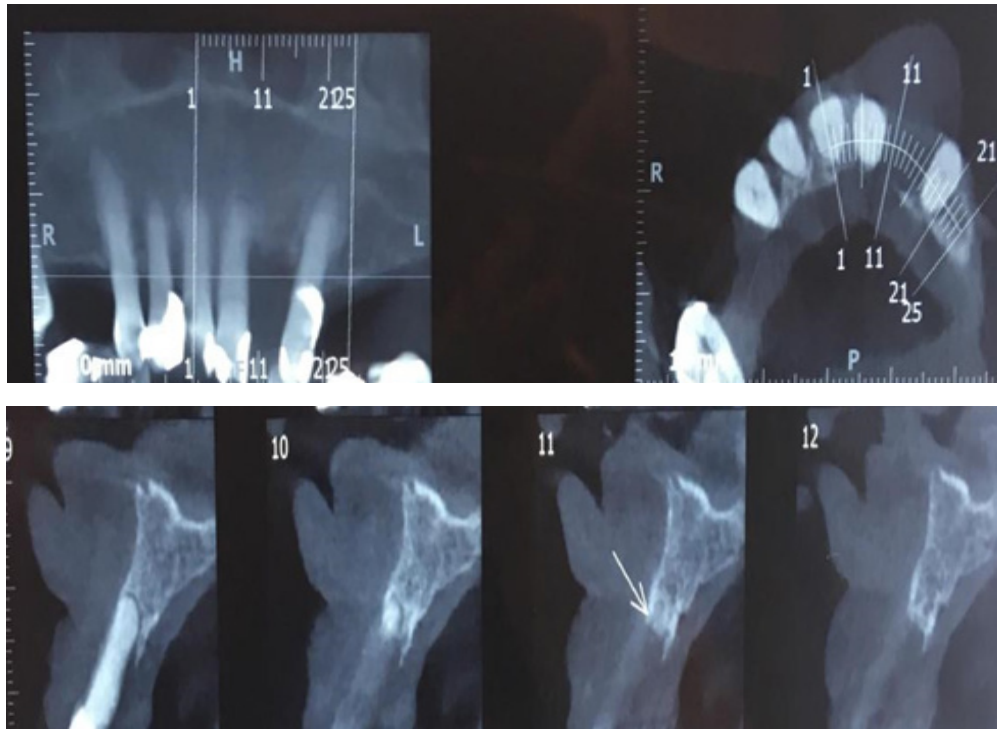
Figure 2: Occlusal view of the same lesion



The first diagnostic hypothesis is a reactive inflammatory lesion, possibly a peripheral giant-cell granuloma. A CT was ordered to assess the underlying bone, presence or absence of bone resorption, or central lesion. The image

shows that tooth 2.2 was missing and that there was chronic periodontal disease, with no bone alterations associated with the lesion to biopsy (fig. 3).

Figure 3: Microtomography. Tooth 2.2 was missing. No bone alteration.



Renal metastasis was considered a differential diagnosis due to the patient's medical history.

The patient was asked to come to the following appointment with a histopathological report of the nephrectomy performed and to coordinate the incisional biopsy of the oral lesion for the following week. The lesion had increased in size significantly by the second appointment

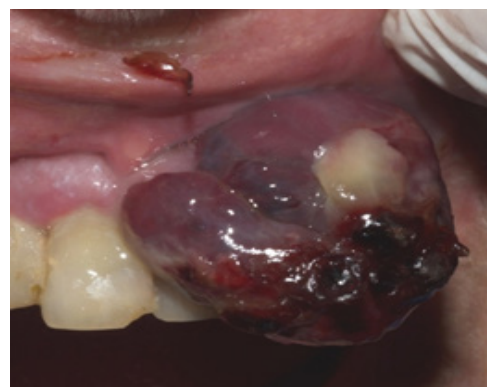
(fig. 4 and 5). The histopathological result of the nephrectomy performed was clear cell renal carcinoma.

A presumptive diagnosis of renal metastasis was made before the biopsy because of the growth rate observed in one week and the previous renal lesion diagnosis.

Figure 4: occlusal view

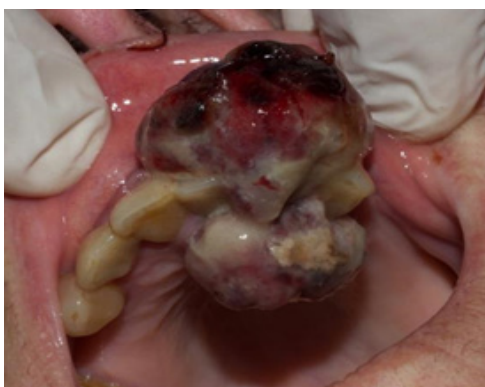

Figure 5: front view



A different strategy was used during the incisio-
nal biopsy: the clinician decided to remove the
entire clinically visible lesion to control intraope-

orative bleeding and achieve proper hemostasis.
Teeth 2.1 and 2.3 were extracted to help hemo-
stasis. (fig. 6 and 7).

Figure 6: tumor excision and
extraction of teeth 2.1

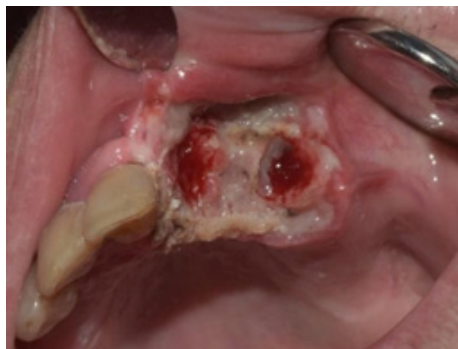
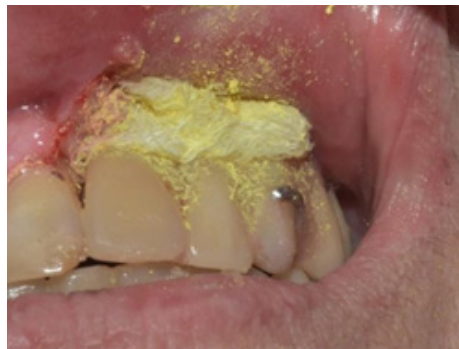
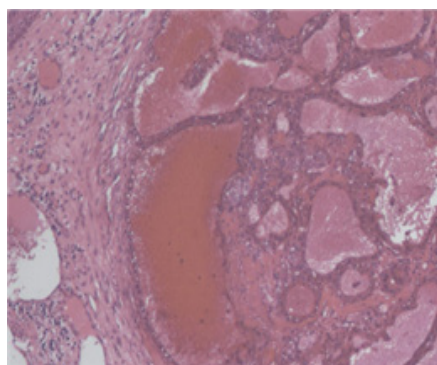
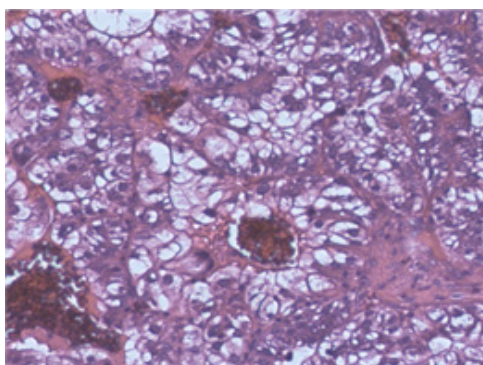
Figure 7: immediate postoperative
period



The tissue was sent for histopathological exa-
mination, which confirmed that the lesion was
a metastatic carcinomatous neoplasm with clear

cells alternating with granular cytoplasmic cells
and very rich vascularization (figures 8 and 9).

Figures 8 and 9: courtesy of Prof. Dr. J. Carzoglio. Histological section of clear cell epithelial neo-
plasm. Major vascularization.



The patient was referred to her oncologist for ge-
neral assessment and possible treatment.
The patient underwent a PET scan—among
several studies—to stage the cancer. The scan
showed multiple metastases throughout the
body. She died a month and a half after the histo-
pathological diagnosis of her oral lesion.

Discussion

Renal cell carcinoma is a malignant pathology
that is difficult to diagnose and is often diagno-
sed late.⁽¹⁰⁾

It accounts for 3% of adult malignancies and 2%
of cancer deaths. Its initial presentation is by me-

tastasis, resulting in a poor prognosis due to late
diagnosis.⁽¹⁰⁻¹²⁾

It frequently affects men aged between 30 and
60⁽¹³⁾ and can metastasize to any part of the body.
It has a 15% risk of metastasis to the head and
neck when the disease is disseminated and a 1%
risk when it is not.⁽¹¹⁾

The literature indicates an interval of 5 to 36
months between the appearance of the primary
tumor and metastasis. Metastases have even
been found decades after surgical excision of the
primary renal tumor.⁽¹⁾ Diagnosis is more diffi-
cult in patients without a history of malignant
nephropathy.^(10,14) A comprehensive analysis of

the literature recently showed a significant association between gingival metastasis and the presence of teeth, suggesting the potential role of inflammation in the distribution of metastatic deposits in the gingiva. The microenvironment of a chronically inflamed gingiva may provide a favorable site for circulating tumor cells to colonize the area and proliferate.⁽⁷⁾

Clinically, an oral metastasis of the oral soft tissues appears as an exophytic, sometimes ulcerated lesion. Early lesions, mainly those in the gingiva, such as gingival enlargements, are similar to benign hyperplastic or reactive lesions, such as pyogenic granuloma, peripheral giant cell granuloma, or fibroma.⁽⁷⁾ The disease progression may include symptoms such as pain, bleeding, infection, dysphagia, interference with chewing, and facial deformity.^(6,7) Severe hemorrhagic epi-

sodes have been reported after biopsy in some cases, especially in metastatic hepatocellular carcinomas.⁽¹⁵⁾

The evolution of most patients with an oral metastatic lesion is unfavorable, with a mortality rate of over 90% at 5 years.⁽¹⁶⁾

In the case described, the patient's evolution was in line with the literature. The oral metastasis diagnosed was the initial diagnosis of several metastases that she presented.

Conclusions

Diagnosing oral metastases is a challenge for practitioners, especially when the primary tumor is unknown. The main challenge is early detection and differential diagnoses of benign inflammatory and reactive oral lesions. Primary malignancies of the oral cavity should always be considered.

References

1. Sountoulides P, Metaxa L, Cindolo L. Atypical presentations and rare metastatic sites of renal cell carcinoma: a review of case reports. *J Med Case Rep.* 2011;5:429. Doi:10.1186/1752-1947-5-429
2. Allon I, Pessing A, Kaplan I, Allon DM, Hirshberg A. Metastatic tumors to the gingiva and the presence of teeth as a contributing factor: a literature analysis. *J Periodontol.* 2014;85(1):132-9. Doi: 10.1902/jop.2013.130118
3. Hirshberg A, Leibovich P, Buchner A. Metastases to the oral mucosa: analysis of 157 cases. *J Oral Pathol Med.* 1993;22(9):385-90. Doi:10.1111/j.1600-0714.1993.tb00128.x
4. Hirsheberg A, Buchner A. Metastatic tumours to the oral region. An overview. *Oral Onco. Eur J Cancer.* 1995;31B (6):355-60. Doi: 10.1016/0964-1955(95)00031-3
5. Hirsheberg A, Leibovich P, Buchner A. Metastatic tumors to the jaws: analysis of 390 cases. *J Oral Pathol Med.* 1994;23(8):337-41. Doi:10.1111/j.1600-0714.1994.tb00072.x
6. Hirsheberg A, Shnaiderman-Shapiro A Kaplan I, Berger R. Metastatic tumours to the oral cavity-pathogenesis and analysis of 673 cases. *Oral Oncol.* 2008;44(8):743-52. Doi:10.1016/j.oraloncology.2007.09.012
7. Servato JP, de Paulo LF, de Faria PR, Cardoso SV, Loyola AM. Metastatic tumours to the head and neck: retrospective analysis from a Brazilian tertiary referral centre. *s.l: Int J Oral Maxillofac Surg.* 2013;42(11):1391-6. Doi:10.1016/j.ijom.2013.05.020
8. D'silva N, Summerline DJ, Cordell KG, Abdelsayed RA, Tomish CE, Hanks CT, Fear D, Meyrowitz S. Metastatic tumors in the jaws. A retrospective study of 114 cases. *JADA.* 2006;137(12):1667-72. Doi:10.14219/jada.archive.2006.0112

9. Hirshberg A, Berger R, Allon I, Kaplan I. Metastatic Tumors to the Jaws and Mouth. *Head and Neck Pathol* 2014;(8):463-474. Doi:10.1007/s12105-014-0591-z
10. Vallalta Morales M, Todolí Parra J, Cervera Miguel JI, Calabuig Alboroch JR. Right hemiparesia as presentation of renal cell carcinoma. *An Med Interna*. 2004 Jul;21(7):359-60. Doi:10.4321/s0212-71992004000700010
11. Maestre-Rodriguez O, Gonzales-García R, Mateo-Arias J, Moreno-Garcia C, Serrano-Gil H, Villanueva-Alcojol L, Campos-de-Orellana AM, Monje-Gil F. Metastasis of renal clear-cell carcinoma to the oral mucosa, an atypical location. *Med Oral Patol Oral Cir Bucal* 2009;14:601-604. Doi:10.4317/medoral.14.e601
12. Sikka S, Sikka P, Kaur G, Shetty DC. A review of histopathological and immunohistochemical parameters in diagnosis of metastatic renal cell carcinoma with a case of gingival metastasis. *J Cancer Res Ther* 2012;9:105-107. Doi:10.4103/0973-1482.110395
13. Aguirre A, Rinaggio J, Diaz-Ordaz E. Lingual metastasis of renal cell carcinoma. *J Oral Maxillofac Surg*. 1996 Mar;54(3):344-6. Doi:10.1016/S0278-2391(96)90757-0
14. Friedlander AH, Singer R. Renal adenocarcinoma of the kidney with metastasis to the tongue. *J Am Dent Assoc*. 1978 Dec;97(6):989-91. Doi:10.14219/jada.archive.1978.0420
15. Ahsar A, Khateery SM, Kovacs A. Mandibular metastatic hepatocellular carcinoma: a case involving severe post biopsy hemorrhage. *J Oral Maxillofac Surg*. 1997;55(6):547-52. Doi:10.1016/s0278-2391(97)90480-8
16. Chow W, Devesa SS, Warren JL, Fraumeni, Jr JF. Rising Incidence of Renal Cell Cancer in the United States. *JAMA*. 1999;281(17):1628-1631. Doi:10.1001/jama.281.17.1628

Conflict of interest declaration:

The authors have no conflict of interest regarding the publication of this paper.

Authorship contribution

1. Conception and design of study
2. Acquisition of data
3. Data analysis
4. Discussion of results
5. Drafting of the manuscript
6. Approval of the final version of the manuscript

FS ha contribuido en 1, 2, 3, 4, 5 and 6.

EP ha contribuido en 1, 2, 3, 4, 5 and 6.

Acceptance note:

This article was approved by the journal's editor, MSc Dr. Vanesa Pereira-Prado.