

Triple fusion in the primary dentition: an unusual case



CASE REPORT

Fusión triple en dentición primaria: reporte de un caso inusual

Fusão tripla na dentição decídua: um caso em comum

Abstract

Tooth development can present changes and alterations in the shape, size, structure, and number of teeth. Among the quantity anomalies are supernumerary teeth, which develop in addition to the typical number of teeth. On the other hand, fusion is an anomaly of form that results from the union of two dental germs, which can be complete or incomplete depending on the stage of development. Dental fusion, which can result in double teeth or a split crown, is relatively common, with a prevalence of 0.1% to 2.5%; However, three-tooth fusion, known as “triple tooth,” is a rare anomaly, with a prevalence of 0.02% in the primary dentition. We present the unusual case of a 5-year-old boy with a triple fusion in his primary dentition between two lower incisors and a supernumerary tooth.

 Natalia Gutiérrez-Marín ¹
 María Fabiola Chevez Briceño ¹

CORRESPONDENCE
Natalia Gutiérrez-Marín:
natalia.gutierrez@ucr.ac.cr

RECEIVED: January 11, 2024
ACCEPTED: September 10, 2024



Keywords: tooth abnormalities, fused teeth, supernumerary tooth, deciduous tooth.

¹ Docente Departamento de Odontopediatría y Ortodoncia, Facultad de Odontología, Universidad de Costa Rica

² Estudiante de Licenciatura, Facultad de Odontología, Universidad de Costa Rica.

Resumen

El desarrollo dental puede presentar cambios y alteraciones en la forma, tamaño, estructura y cantidad de dientes. Dentro de las anomalías de cantidad se encuentran los dientes supernumerarios, los cuales se desarrollan en adición a la cantidad típica de dientes. Por su parte, la fusión es una anomalía de forma que resulta de la unión de dos gérmenes dentales, pudiendo ser completa o incompleta según el estado de desarrollo. La fusión dental, que puede resultar en dientes dobles o una corona dividida, es relativamente común, con una prevalencia del 0,1% al 2,5%; sin embargo, la fusión de tres dientes, conocida como “diente triple”, es una anomalía poco frecuente, con una prevalencia del 0,02% en la dentición primaria. Se reporta el caso inusual de un niño de 5 años con una triple fusión en su dentición primaria entre dos incisivos inferiores y un diente supernumerario.

Palabras clave: anomalías dentales, dientes fusionados, diente supernumerario, diente primario.

Resumo

O desenvolvimento dentário pode apresentar alterações e alterações na forma, tamanho, estrutura e número de dentes. As anormalidades quantitativas incluem dentes supranumerários, que se desenvolvem além do número típico de dentes. Por outro lado, a fusão é uma anomalia da forma que resulta da união de dois gérmenes dentários, que podem ser completos ou incompletos dependendo do estágio de desenvolvimento. A fusão dentária, que pode resultar em dentes duplos ou coroa dividida, é relativamente comum, com prevalência de 0,1% a 2,5%; No entanto, a fusão de três dentes, conhecida como “dente triplo”, é uma anomalia rara, com prevalência de 0,02% na dentição decídua. Apresentamos o caso incomum de um menino de 5 anos com uma tripla fusão na dentição decídua entre dois incisivos inferiores e um dente supranumerário.

Palavras-chave: anormalidades dentárias, dentes fusionados, dente supranumerário.

Introduction

A dental developmental defect refers to any change or alteration in the teeth that differs from their normal structure. These changes or anomalies can be grouped into four main categories, including alterations in the shape, size, structure, and number of teeth ⁽¹⁾.

Included in the quantity anomalies are supernumerary teeth, also known as hyperdontia, which are those that develop in addition to the typical number of teeth. They can arise in any area of the maxillae, although there is a preference for the upper anterior area. They can appear as single or multiple teeth, on one side or both sides ⁽²⁾. The prevalence in permanent dentition ranges from 0.5% to 5.3%, and in primary dentition from 0.2% to 0.8% ^(3,4). Supernumerary teeth may be associated with a syndrome, or they can appear in individuals without any specific medical condition ⁽⁵⁾. Generally, a higher prevalence of supernumerary teeth is observed in males than in females ^(4,6). In turn, shape anomalies are frequently encountered in the daily practice of dentistry, appearing in various forms: fusion, gemination, concrescence, and dilaceration ⁽⁷⁾. Fusion is the result of the union of two normally separate dental germs. This fusion occurs during the morphodifferentiation stage of the tooth germs, and the final outcome is determined by the developmental

stage of the involved teeth. The degree of fusion can be complete or incomplete. If fusion occurs early, the two growing teeth may fuse, giving the appearance of a single, normal-sized tooth. However, if it occurs at a later stage of development, the result may be a double-sized tooth or a tooth with a split crown ⁽⁸⁾. The etiology of fused teeth is not entirely clear. It has been associated with the involvement of the neural crest in dental development, traumatic or inflammatory factors affecting the follicles, high doses of vitamin A, persistence of the interdental lamina, or an autosomal dominant inheritance pattern ^(9,10).

Fused teeth are more common in primary dentition than in permanent dentition, with a reported prevalence ranging from 0.1% to 2.5%, and this fusion typically occurs unilaterally ⁽¹¹⁾. Their most frequent location is the anterior region, often involving the lateral incisors and mandibular canines ⁽¹²⁻¹⁴⁾. The union of three primary dental germs is extremely rare; one study reports a prevalence of 0.02%, where this triple union may result from fusion, gemination, or concrescence ⁽¹⁵⁾.

This article aims to present an unusual case of a triple fusion between two primary lower incisors and a supernumerary tooth.

Background:

ANAMNESIS

A 5-year-old boy presented to the Pediatric Dentistry and Orthodontics Clinic at the Faculty of Dentistry, University of Costa Rica, accompanied by his mother. The reason for consultation was the patient's caries, which required urgent attention for rehabilitation. The child's mother reported that the boy was healthy, with no history of systemic diseases, and that he had suffered a soft tissue trauma at the age of 2, resulting in a lip contusion.

CLINICAL EXAMINATION.

During the intraoral clinical examination, performed with a mouth mirror and artificial light in the dental chair, the following was observed: primary dentition with biofilm

accumulation, cavitated carious lesions in the primary molars, and two supernumerary teeth—one in the left upper anterior region and the other in the lower anterior region, fused with the right central and lateral incisors. Two vertical grooves were present on the labial and lingual surfaces at the junction of the fused teeth. There were no carious lesions, and the surrounding periodontium was healthy. The upper anterior section showed an anterior crossbite involving one tooth, and in the mandibular region, slight gyroversion was observed in the left primary central incisor and the fused teeth (Figure 1 A, B, and C).

The mother stated there was no family history of dental anomalies and that she was unaware of the fused teeth in her son.

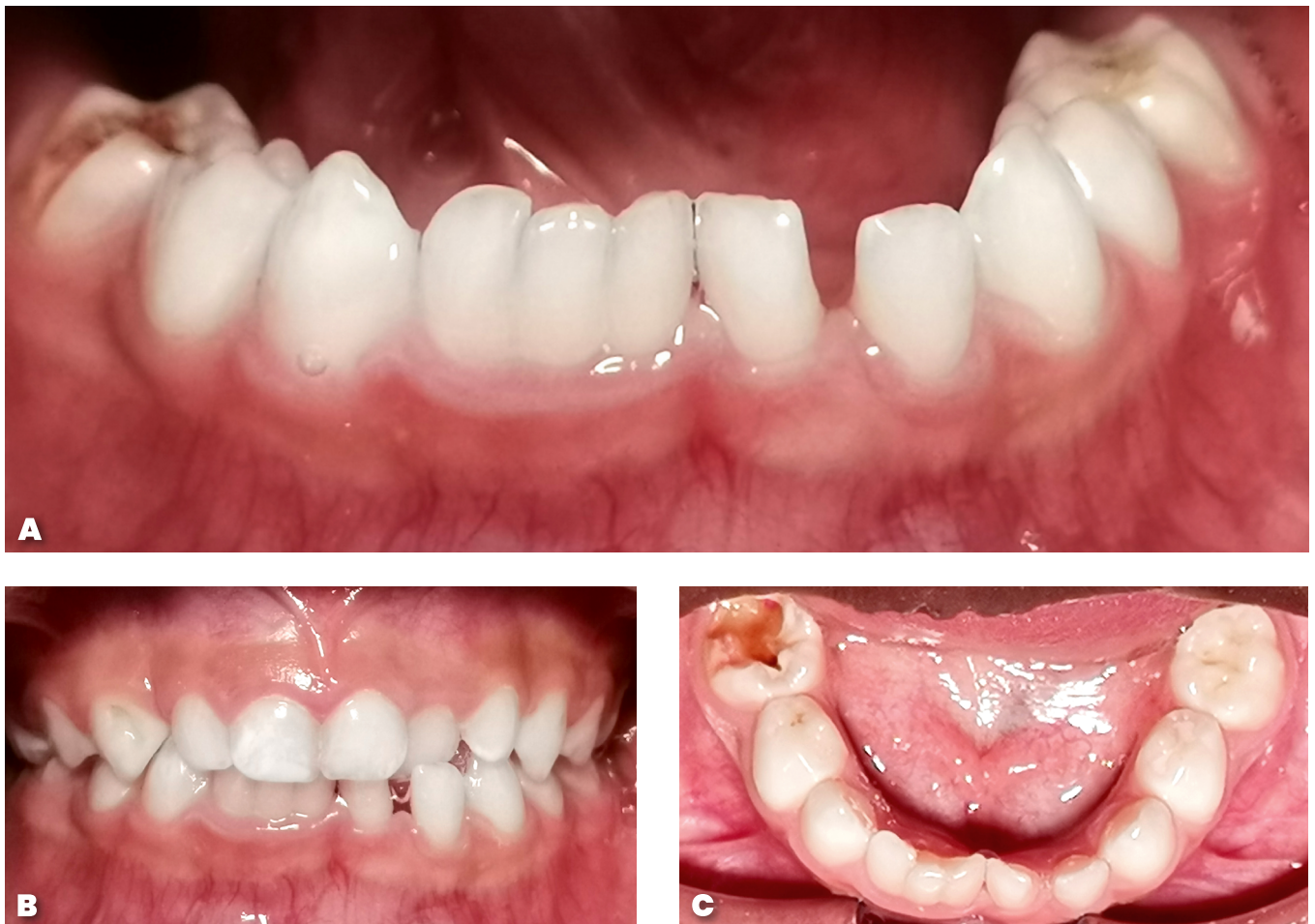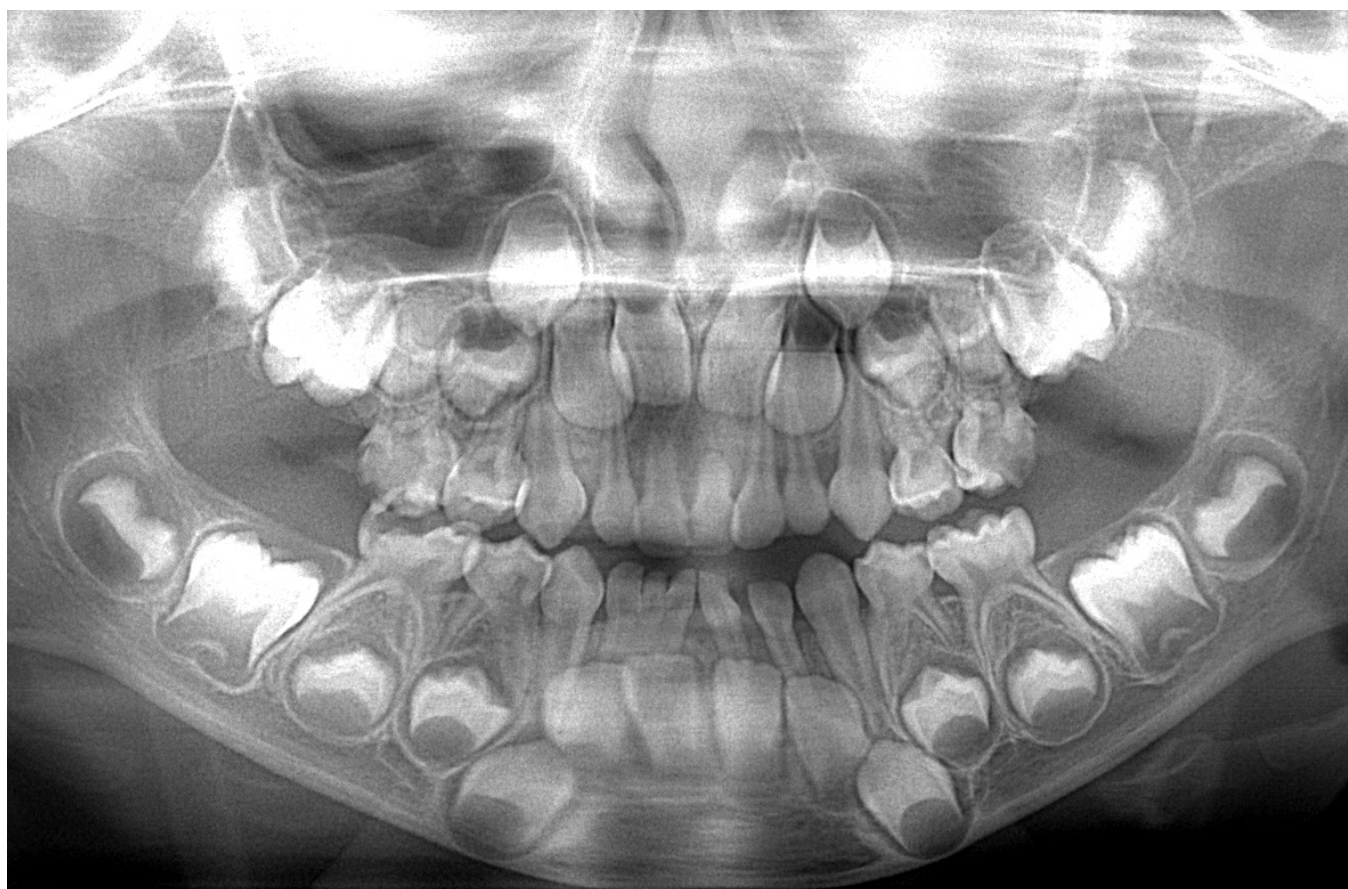
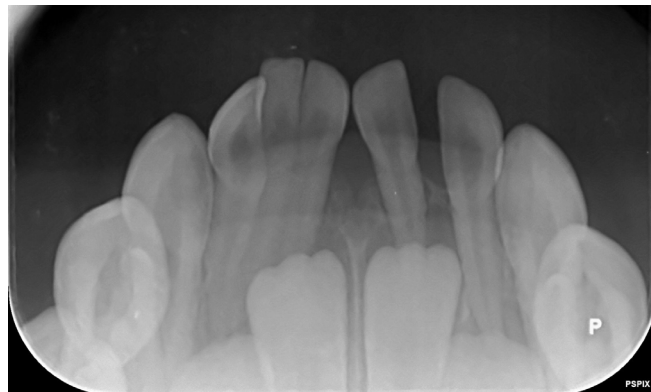


Figure 1.

- A. Frontal view of the maxillae.
- B. Frontal view of the fused teeth.
- C. Occlusal view showing a gyroversion of the lower primary incisors.

IMAGING TEST

right primary incisors with a supernumerary tooth, showing separate pulp chambers and root canals. Additionally, the developing right and left permanent central and lateral incisors were visible. The panoramic radiograph displayed all developing permanent tooth germs, with no detected dental anomalies (Figure 2).



A hemimaxillary tomography was performed using J. MORITA MFG equipment, with a voxel size of 0.125 mm; i-Dixel software was utilized. The radiologist's report stated: "Teeth 8.1 and 8.2 are fused, with additional fusion involving a supernumerary tooth. The three teeth are connected by their crowns and roots, each with its own pulp chamber and root canal." The axial section confirmed the fusion at the dentin level for all three teeth, while the tangential section revealed distinct pulp chambers and root canals. The transaxial section showed the lingualized position of the lower right permanent incisor (Figure 3).

Figure 2. Intraoral periapical anteroinferior and panoramic radiograph.

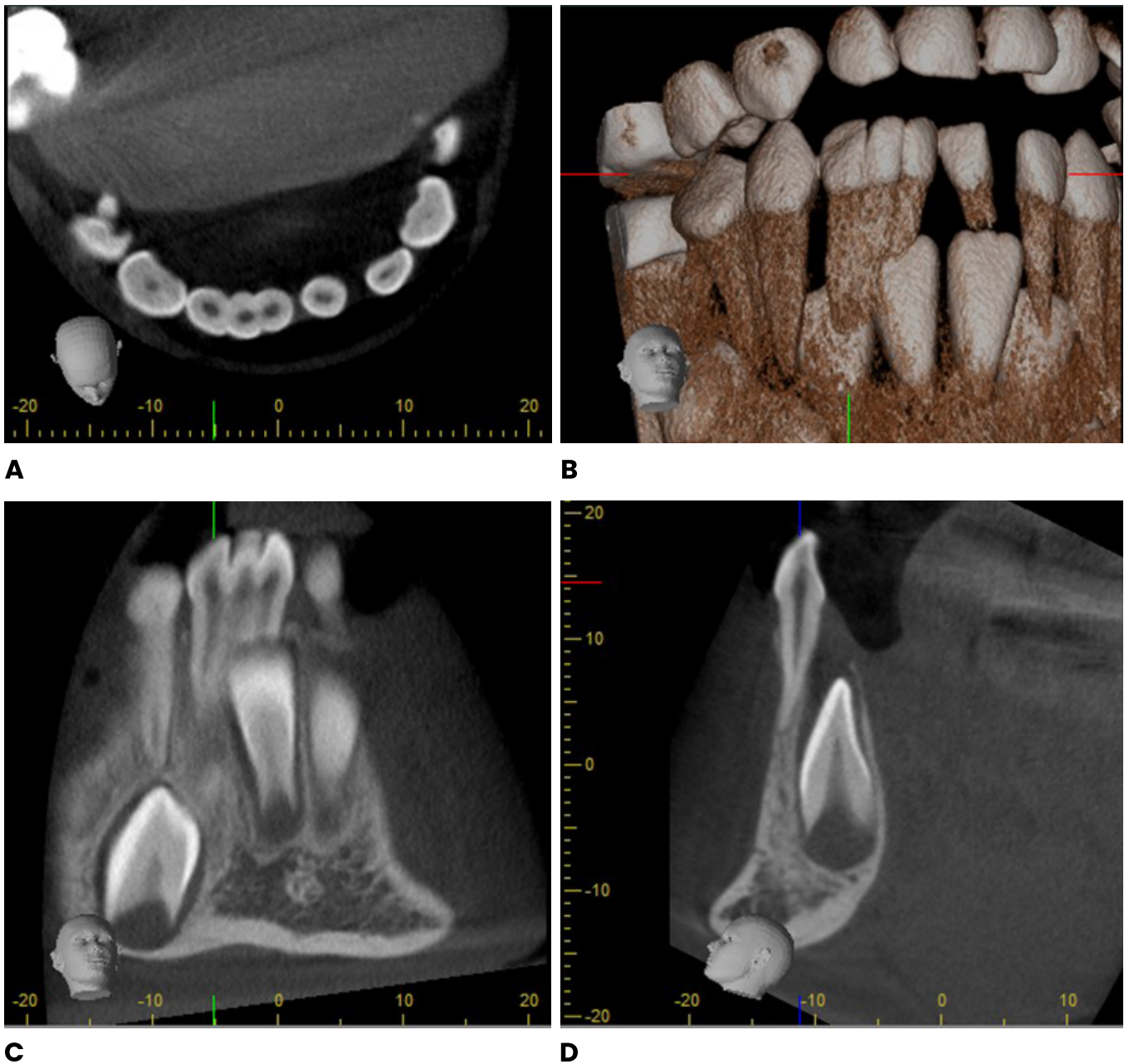


Figure 3. Computed axial tomography of fused teeth.

- A. Axial section.
- B. Three-dimensional reconstruction
- C. Tangential section.
- D. Transaxial section.

FOLLOW-UP AND CHECK-UPS

The lower permanent central incisors were actively erupting, with no signs of accelerated eruption. It was decided to retain the fused teeth in the mouth and conduct regular follow-up visits to assess the exfoliation process. Regarding the anterior crossbite and the upper supernumerary tooth, both were kept under observation in accordance with the orthodontist's recommendations.

Imaging control was performed three months later, and the intraoral radiograph showed that the permanent lower teeth continued their eruption process similarly, resorbing part of the root of the primary lower left

incisor, as well as part of the roots of the fused central and supernumerary teeth. However, the root of the fused lateral incisor did not appear to resorb in the same way as the other fused teeth (Figure 4). The fused teeth were kept in the mouth, with another check-up scheduled four months later.

After four months, the child returned for another clinical check-up. The permanent lower left incisor had now erupted, but the fused teeth remained in the mouth, exhibiting grade II mobility. An intraoral radiograph showed

that the roots of the central incisor and the supernumerary tooth had resorbed, with only less than one-third of the root of the lateral incisor remaining (Figure 5).

The child reported pain when chewing with the fused tooth, likely due to its mobility, leading to the decision to extract it (Figure 6). The extraction was performed using half a cartridge of 2% anesthetic with 1:80,000 epinephrine (ODDONTO Lido®, New Stetic S.A., Colombia), employing vestibular and lingual infiltrative anesthetic techniques.

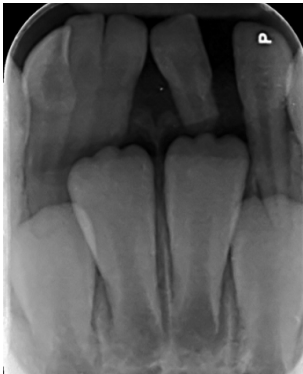

Figure 4. Little root resorption of the fused right primary lateral root is observed.

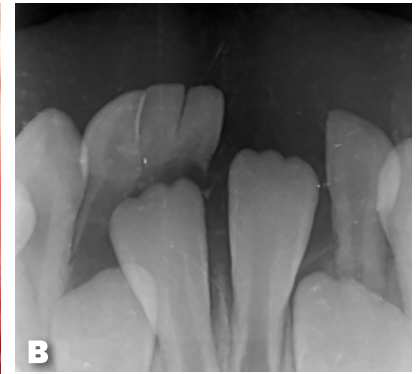
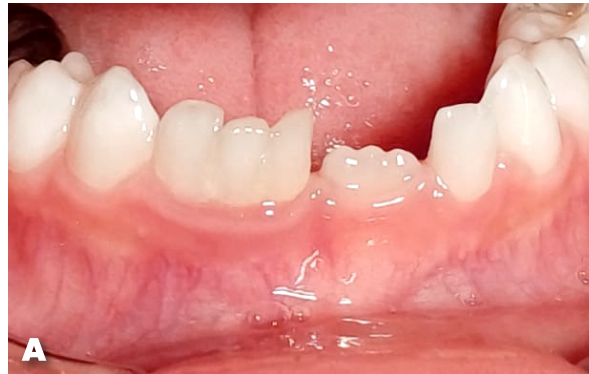

Figure 5.
A. Eruption of the lower left permanent incisor.
B. Fused teeth with significant root resorption.

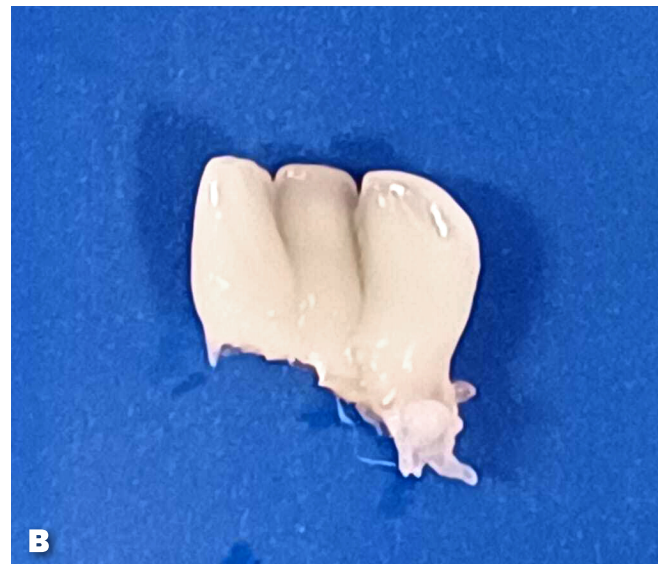
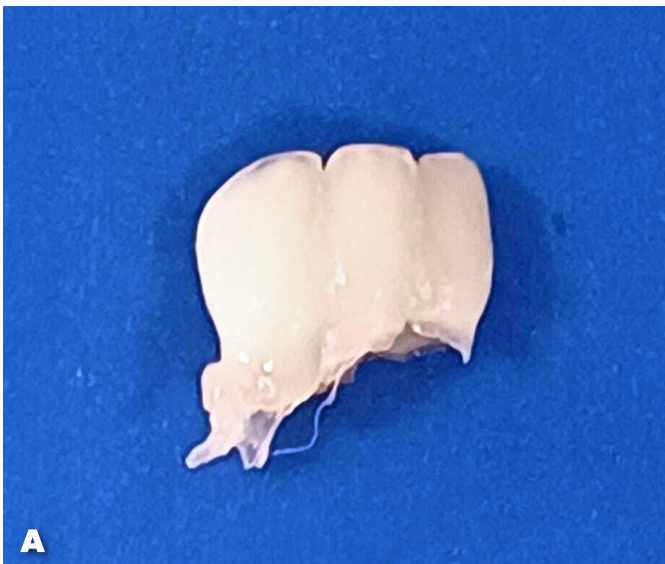
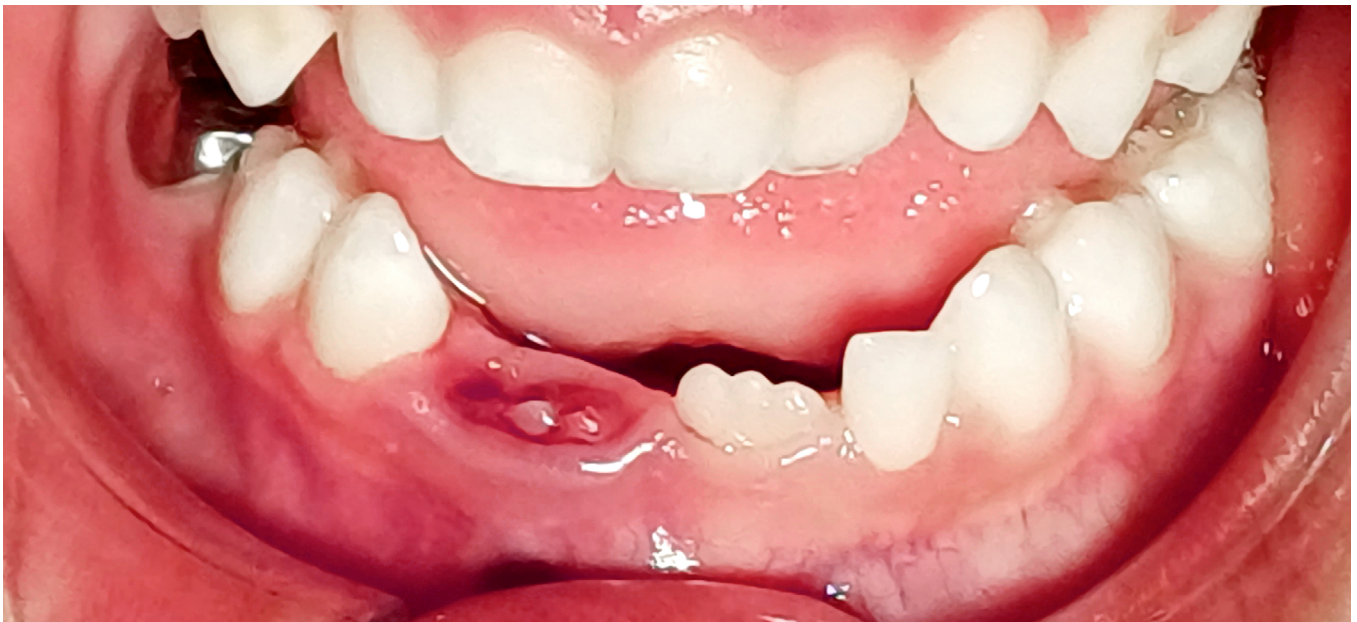Figure 6.
A. Frontal view of fused teeth.
B. Lingual view of fused teeth..

Following the extraction, the incisal edge of the lower right permanent central incisor was observed in the process of active eruption (Figure 7). It was recommended

to schedule three-month check-ups to monitor the tooth replacement process, with particular attention to the lower right lateral incisor.



Written free and informed consent was obtained from the child's mother for the publication of this case.

Figure 7. Part of the incisal edge of the lower right permanent incisor can be seen.

Discussion

As dentists, encountering a patient with a supernumerary tooth or dental fusion is a relatively common finding in clinical practice. However, the triple fusion of two primary teeth with a supernumerary tooth, as in this case, is an unusual occurrence.

According to the literature, triple teeth tend to have a preference for the left side of the maxilla⁽¹⁴⁾. In this case, however, the triple fusion occurred on the right side of the mandible. One consistent finding with other studies is that fusions in primary teeth generally occur unilaterally, as seen in this case^(16,17).

Fused teeth can lead to complications such as caries and periodontal issues⁽¹⁶⁾. In this case, despite the presence of retention grooves on the vestibular and lingual surfaces of the fused teeth, they were caries-free. Additionally, the surrounding gingiva was neither erythematous nor swollen, which is notable given that the child exhibited significant biofilm accumulation and cavitated carious lesions in his primary molars. Another potential complication of dental fusion is aesthetic concerns⁽⁷⁾, which were not present in this case. The mother reported that

both she and the patient were unaware of the fused teeth, believing that the child's teeth were fine aside from the caries.

Moreover, fused teeth can cause malocclusions, lack of space, and delayed eruption of succedaneous teeth⁽¹¹⁾. In this case, although the fused teeth were slightly rotated, they did not compromise the space of the adjacent teeth. Tomography revealed that the eruption process of the lower permanent central incisors was similar.

The management of dental fusions in primary dentition is case-dependent, requiring consideration of the patient's age, the presence of the germ of the succedaneous tooth, and whether the fusion is causing retention of permanent teeth⁽¹¹⁾. Treatment options range from periodic monitoring, fluoride application, sealing of existing grooves, to extraction of the fused teeth^(7,15). In this case, it was decided to retain the fused teeth without sealing the vestibular and lingual grooves, as the tooth replacement process was imminent. Additionally, the fused teeth were maintained since clinical and radiographic follow-ups indicated they did not affect the erup-

tion process of the succedaneous teeth. Had premature exodontia of the fused teeth been performed, it could have affected the eruption pathway of the lower right permanent central tooth ^(18,19).

Regular check-ups are essential, as the premature exfo-

liation of the primary lateral can lead to the distalization of the right lower permanent central. This could result in a dental midline deviation and reduced space for the eruption of the right lower permanent lateral incisor.

Conclusion

Dental fusions in primary dentition can lead to complications ranging from caries and periodontal issues to malocclusions and aesthetic concerns. A timely clinical diagnosis, along with radiographic examination, is important for detecting dental anomalies and providing the most appropriate individualized treatment based on scientific evidence.

REFERENCES

1. Kashmoola MA, Diagnosis, OralMustafa N, Noor S, Rozaimie R, Ameer F. Prevalence of Developmental Dental Anomalies and Defects: a clinical survey. *J Int Dent Med Res.* 2021;14(1):265–72.
2. Timothy CN, Kiran D, Nabeel P, Maiti S. Presence of impacted supernumerary teeth in the Indian population. *J Adv Pharm Technol Res.* 2022;13:427–31.
3. Wang X, Fan J. Molecular Genetics of Supernumerary Tooth Formation. *Genesis.* 2011;49:261–77.
4. Hajmohammadi E, Najirad S, Mikaeili H, Kamran A. Epidemiology of Supernumerary Teeth in 5000 Radiography Films : Investigation of Patients Referring to the Clinics of Ardabil in 2015 – 2020. *Int J Dent.* 2021;2021:6669436.
5. Vazquez D. Dientes supernumerarios: Estudio de prevalencia en la ciudad de Buenos Aires. *Rev ADM.* 2012;LXIX(5):222–5.
6. Cammarata-scalisi F, Avenda A, Callea M. Main genetic entities associated with supernumerary teeth. *Arch Argent Pediatr.* 2018;116(6):437–43.
7. Bernardi S, Bianchi S, Bernardi G, Tchorz JP, Attin T, Hellwig E, et al. Clinical management of fusion in primary mandibular incisors: a systematic literature review. *Acta Odontol Scand [Internet].* 2020;78(6):417–24.
8. Leen V, Rupandeep S. Bilateral Fusion in deciduous dentition associated with bolateral fusion in succadeneous permanent teeth - a case report. *Indian J Dent Sci.* 2013;5(1):53–5.
9. Iglesia-Puig, M. Á., Arellano-Cabornero, A., & López-Areal García, B. Anomalías dentarias de unión: fusión dental. *Rcoe.* 2005;10(2), 209-214.
10. Peña, Reyes, Anselmi, Barrera, González, Rodríguez. Anomalías dentarias: Fusión dental, abordaje endodóntico. *Revista de la Facultad de Odontología. Universidad Nacional de Cuyo.* 2021;15(1):38-43.
11. Costa A, Nascimento B, Silvia J, Santos A, Cruz S, Fernandes M. Fused teeth in the primary dentition: clinical case report. *REv Gauch Odontol.* 2020;68:1–6.
12. León M. Anomalías dentarias de unión en dientes deciduos, un desafío en la práctica clínica. Tesis. 2023. <https://dspace.uhemisferios.edu.ec/items/3df7b8ec-844f-40d5-aef4-b9e63653eb73>
13. Salem M Ben, Chouchene F, Masmoudi F, Baaziz A, Maatouk F, Ghedira H. Case Report Fusion or Geminatio? Diagnosis and Management in Primary Teeth : A Report of Two Cases. *Case Rep Dent.* 2021;2021:1–7.
14. Shanthraj SL, Mallikarjun SB, Kiran S, Wilson B. ‘Triplication ’ defect in deciduous teeth : an unusual odontogenic anomaly. *BMJ Case Rep.* 2015;10–3.
15. Shilpa G, Nuvula S. Triple tooth in primary dentition : A proposed classification. *Contemp Clin Dent.* 2013;4(2):263–7.
16. Miegimolle Herrero M, Espí Mayor M, Imperatore Fusar G, Caley Zambrano AM, Arner Cortina C. Anomalías dentarias de unión temporal: a propósito de un caso. *Odontol Pediatr (Madrid).* 2016;24(2):149–59.
17. Tomizawa M, Shimizu A, Hayashi S, Noda T. Bilateral maxillary fused primary incisors accompanied by succedaneous supernumerary teeth: report of a case. *Int J Paediatr Dent.* 2002;12(3):223–7.
18. Bindayel NA. Clinical evaluation of short term space variation following premature loss of primary second molar, at

early permanent dentition stage. Saudi Dent J. 2019;31(3):311-5.

19. Kaklamanos EG, Lazaridou D, Tsiantou D, Kotsanos N, Athanasiou AE. Dental arch spatial changes after premature loss of first primary molars: a systematic review of controlled studies. Odontology. 2017;105(3):364-74.

Conflict of Interest Statement

The authors declare no conflicts of interest in the publication of this article.

Source of Funding

The authors declare not having a funding source.

Authorship Contribution

FIRST AND LAST NAME	ACADEMIC COLLABORATION													
	1	2	3	4	5	6	7	8	9	10	11	12	13	14
Caio Cesar de Souza Loureiro	X	X	X	X	X	X	X	X	X	X	X	X	X	X
Alberi José Thomas de Souza Júnior			X			X	X		X	X	X			X

- | | |
|-------------------------------|--|
| 1. Project Administration | 8. Methodology |
| 2. Funding Acquisition | 9. Resources |
| 3. Formal Analysis | 10. Writing-Original Draft Preparation |
| 4. Conceptualization | 11. Software |
| 5. Data Curation | 12. Supervision |
| 6. Writing - Review & Editing | 13. Validation |
| 7. Research | 14. Visualization |

Acknowledgements:

To Dr. Patricia Ovaes Saballos, Dentomaxillofacial Radiologist, Faculty of Dentistry, University of Costa Rica.

Acceptance Note:

This article was approved by the journal editor PhD. Dr. Vanesa Pereira-Prado.